

ABO Sample Cases Part 2



The highest commitment to excellence.

Disclaimer

- The following sample questions and answers were composed and vetted by a panel of experts in orthodontics and are intended to provide an example of the types of cases and questions that make up the actual examination.
- During the actual examination, trained examiners, who are all board certified orthodontists, will score responses using rubrics as guides to their decision making.
- Using the rubrics help to create consistency in the decisions the examiners will make as examinees deliver their oral responses. The rubrics are not absolute, as there may be other acceptable answers that are not listed.

Disclaimer Cont.

- The ABO has developed multiple versions of the case-based scenario examination to be used during a test administration cycle. Although the set of cases and questions used on the different versions will not all be the same, all versions follow the same content framework as defined by the practice analysis study.
- Scores will be computed using equating procedures to ensure that all versions are of the same difficulty.
- Review of these sample cases does not guarantee that a candidate will pass the examination.

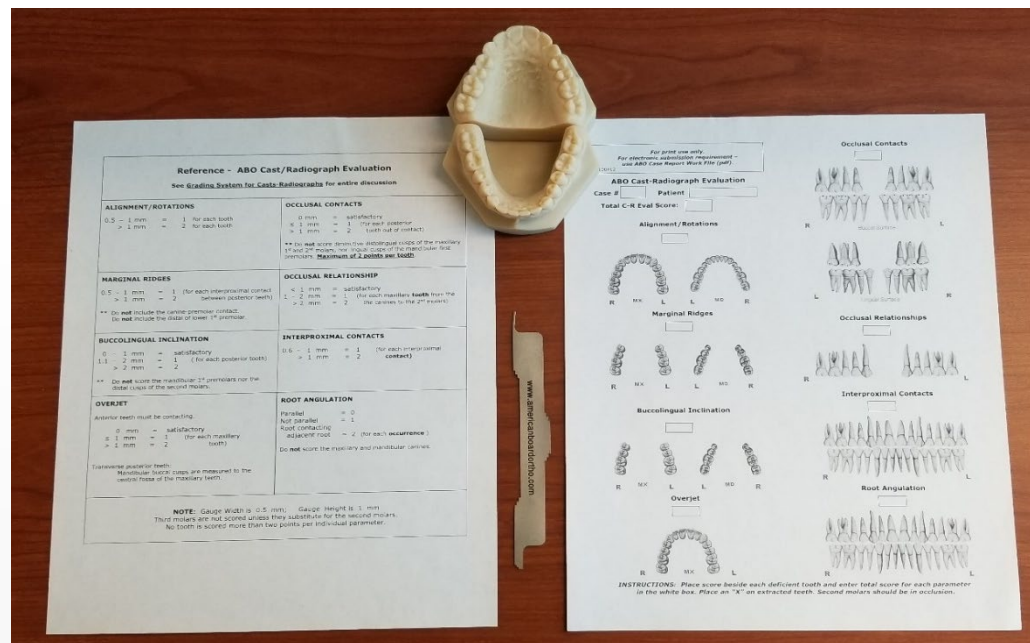
Cast-Radiograph Evaluation Sample Case



The highest commitment to excellence.

Examinee will be presented with the following:

- A set of models
- ABO measuring gauge
- The Grading System Reference for the ABO Cast/Radiograph Evaluation
- CR- Eval worksheet



Examinee will then be asked to score 4 of the following:

- Alignment/Rotations
- Marginal Ridges
- Buccolingual Inclination
- Overjet
- Occlusal Contacts
- Occlusal Relationships
- Interproximal Contacts
- Root Angulation

CR-Eval Sample Question

Question 1

Classification

Domain 4: Critical Analysis and Outcomes Assessment

Prompt

What was the score for the alignment/rotations?

Model Responses

Fully Proficient Model Response: The score is _____.

Borderline Proficient Model Response: The score is _____.

Not Proficient Model Response: The score is _____ or _____.

Superimposition Sample Case

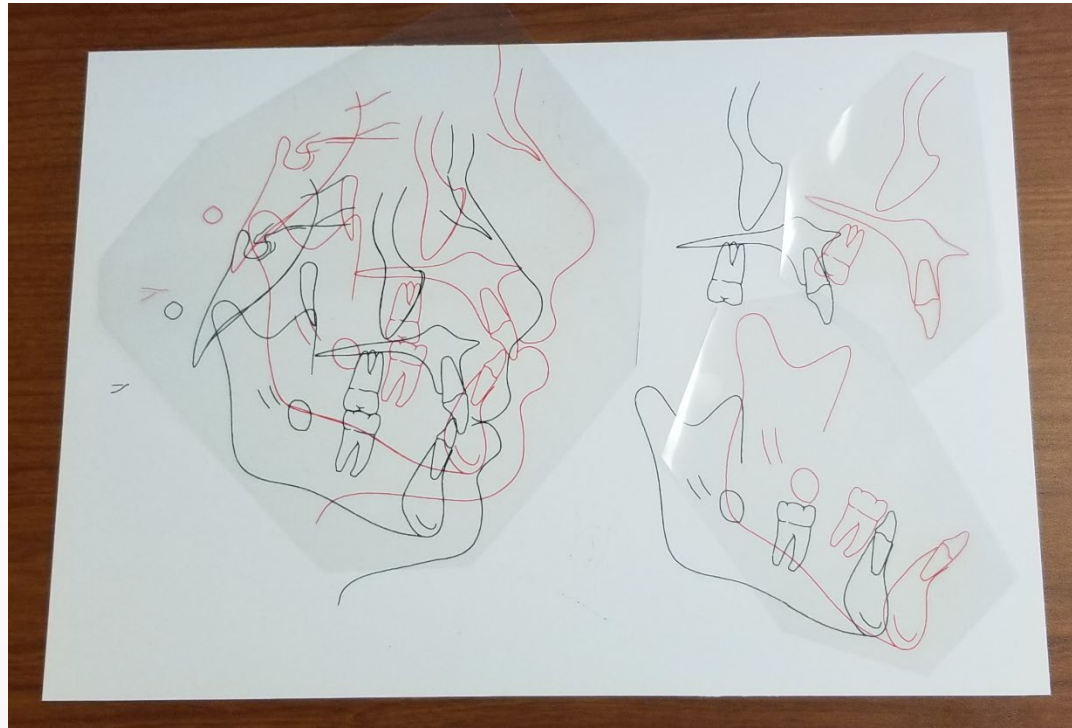

The highest commitment to excellence.

Examinee will be presented with the following case records:

- Initial photo montage
- Initial intraoral photographs
- Initial panoramic radiograph
- Initial lateral cephalogram
- Initial hand-wrist radiograph
- Final photo montage
- Final intraoral photographs
- Final panoramic radiograph
- Final lateral cephalogram

Examinee will also be given the initial cranial base, maxillary, and mandibular tracings printed on cardstock and then asked to superimpose the final tracings that are printed on transparency paper.



Superimposition Sample Question

Question 1

Classification

Domain 4: Critical Analysis and Outcomes Assessment

Prompt

Assuming the time between pre- and post-treatment records was 34 months, what dental changes occurred as a direct result of treatment?

Model Responses

The board expects a fully proficient response for this case to include five dental changes and a borderline proficient response to include at least three.

Case Management Form (CMF) Sample Case



The highest commitment to excellence.

CMF Sample Question

Question 1

- The examinee will have access to the following records: Initial photo montage, initial intraoral photographs, initial lateral cephalogram, initial cephalometric tracing, and the pre-treatment skeletal analysis (see example below).

	PRE TX A
SNA°	81.0
SNB°	72.0
ANB°	9.0
SN-MP°**	48.0
FMA°	39.0

CMF Sample Question

Question 1

Classification

Domain 2: Treatment Objectives and Planning

Opening Scenario

A 16-year, 2-month-old female presents with the chief complaint that “My teeth stick out.”

Prompt

Using the lateral cephalometric analysis, identify appropriate skeletal treatment objectives.

Model Responses

The board expects a fully proficient response for this question to include:

- Increase SNB
- Decrease ANB
- Decrease SN-MP
- Decrease FMA

CMF Sample Question

Question 2

- The examinee will have access to the following records: Initial photo montage, initial intraoral photographs, initial lateral cephalogram, initial cephalometric tracing, final photo montage, final intraoral photographs, final lateral cephalogram, final cephalometric tracing, and the pre- /post-treatment skeletal analysis (see example below).

	PRE TX A	PROG A1	POST TX B	DIFF. A-B
SNA°	81.0		81.0	0.0
SNB°	72.0		70.0	-2.0
ANB°	9.0		11.0	2.0
SN-MP°**	48.0		50.0	2.0
FMA°	39.0		41.0	2.0

CMF Sample Question

Question 2

Classification

Domain 4: Critical Analysis and Outcomes Assessment

Opening Scenario

A 16-year, 2-month-old female presents with the chief complaint that “My teeth stick out.”

Prompt

Describe the skeletal changes and your rationale for what occurred.

Model Responses

The board expects a fully proficient response for this question to include:

- Decrease in SNB due to inadequate vertical control
- Increase in ANB due to inadequate vertical control
- Increase SN-MP due to inadequate vertical control
- Increase in FMA due to inadequate vertical control

CMF Sample Question

Question 3

- The examinee will have access to the following records: Initial photo montage, initial intraoral photographs, initial lateral cephalogram, initial cephalometric tracing, and the pre-treatment dental analysis (see example below).

	PRE TX A
<u>1</u> TO NA mm	9.0
<u>1</u> TO SN°	111.0
- 1 TO NB mm	16.0
- 1 TO MP°	107.0

CMF Sample Question

Question 3

Classification

Domain 2: Treatment Objectives and Planning

Opening Scenario

A 16-year, 2-month-old female presents with the chief complaint that “My teeth stick out.”

Prompt

Identify appropriate dental treatment objectives for the variables in the case management table.

Model Responses

The board expects a fully proficient response for this question to include:

- Retract maxillary incisors to NA
- Retract mandibular incisors to NB
- Decrease mandibular incisor proclination to MP
- Decrease maxillary incisor proclination to SN

CMF Sample Question

Question 4

- The examinee will have access to the following records: Initial photo montage, initial intraoral photographs, initial lateral cephalogram, initial cephalometric tracing, final photo montage, final intraoral photographs, final lateral cephalogram, final cephalometric tracing, and the pre- /post-treatment dental analysis (see example below).

	PRE TX A	PROG A1	POST TX B	DIFF. A-B
<u>1</u> TO NA mm	9.0		-2.0	11.0
<u>1</u> TO SN°	111.0		77.0	34.0
⁻ <u>1</u> TO NB mm	16.0		9.0	7.0
⁻ <u>1</u> TO MP°	107.0		97.0	10.0

CMF Sample Question

Question 4

Classification

Domain 4: Critical Analysis and Outcomes Assessment

Opening Scenario

A 16-year, 2-month-old female presents with the chief complaint that “My teeth stick out.”

Prompt

Describe the changes in the maxillary and mandibular incisor position observed in this case.

Model Responses

The board expects a fully proficient response for this question to include:

- Excessive retraction of maxillary incisors
- Lack of torque control in maxillary incisors
- Retraction of mandibular incisors
- Adequate torque control of mandibular incisors