

ABO Sample Cases 2



The highest commitment to excellence.

Disclaimer

- The following sample questions and answers were composed and vetted by a panel of experts in orthodontics and are intended to provide an example of the types of cases and questions that make up the actual scenario-based clinical examination.
- After the examination, trained examiners, who are all board certified orthodontists, will score the typed responses using rubrics as guides to their decision making.
- Rubrics help to create consistency in the decisions the examiners make while grading an examinees typed responses. The rubrics are not absolute, as there may be other acceptable answers that are not listed.

Disclaimer Cont.

- The ABO has developed multiple versions of the case-based scenario examination to be used during a test administration cycle. Although the set of cases and questions used on the different versions will not all be the same, all versions follow the same content framework as defined by the practice analysis study.
- Scores will be computed using equating procedures to ensure that all versions are of the same difficulty.
- Review of these sample cases does not guarantee that a candidate will pass the examination.
- Examinee responses to exam questions will be typed out and should be in bullet point format (i.e., short and concise, no essay responses).

Sample Case #1

Opening Scenario:

A 14-year, 9-month-old female presents with a chief complaint that “I don’t like my bite.”

Sample Case #1

Question 1

Classification

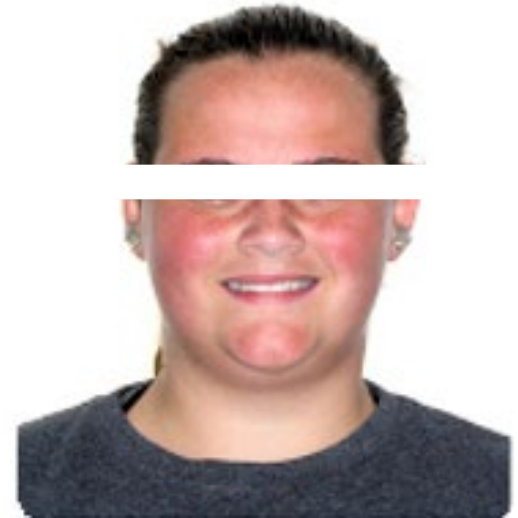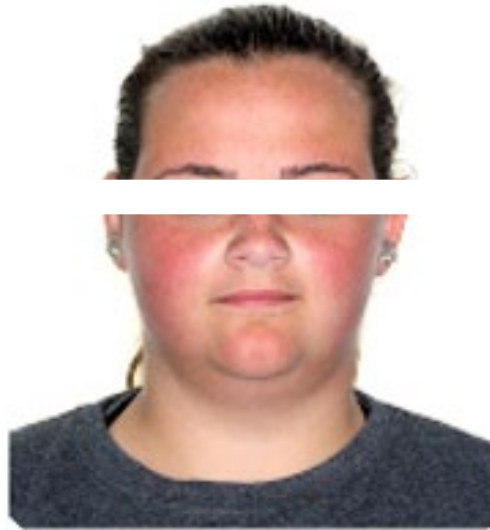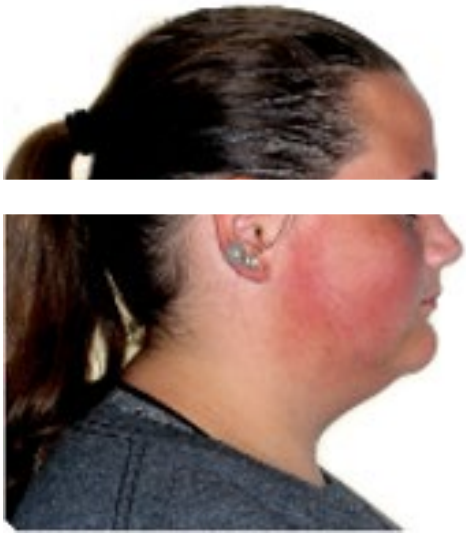Domain 1: Data Gathering and Diagnosis

Prompt

Describe the facial characteristics of this patient.
Please list in bullet point format below.

Sample Case #1

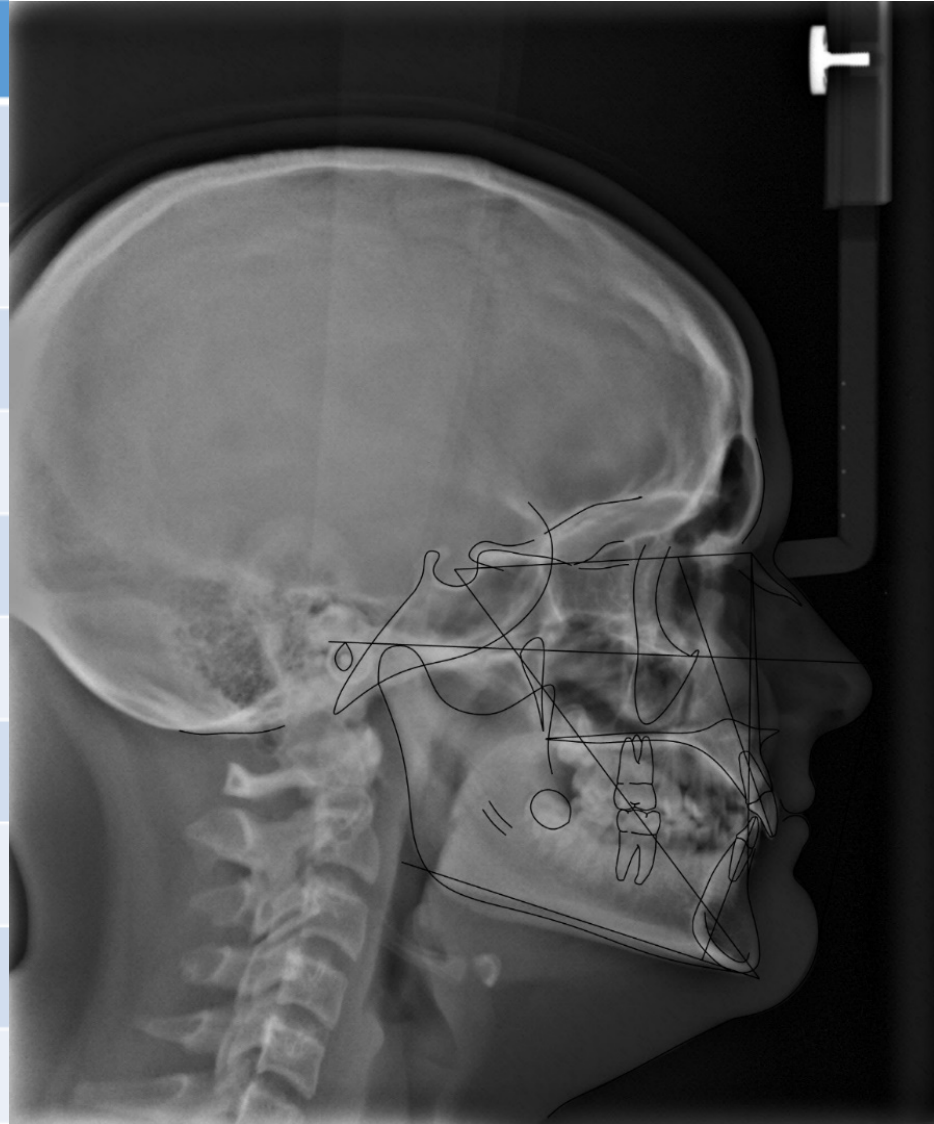
Question 1



Sample Case #1

Question 1

Measure	Value
SNA	89.4
SNB	86.1
ANB	3.2
Wits	-1.6
FMA	15.8
SN- <u>GoGn</u>	19.9
U1-SN	105.6
IMPA	92.6
Upper lip	-8.0
Lower lip	-7.1



Sample Case #1

Question 1

Fully Proficient Model Response

The examinee's response must include six or more of the following:

- Straight profile
- Prominent soft tissue pogonion
- Deep mentolabial sulcus
- Obtuse nasolabial angle
- Obtuse chin-throat angle
- Deficient vermilion display
- Poor maxillary incisor display

Sample Case #1

Question 1

Borderline Proficient Model Response

The examinee's response must include five of the above responses.

Not Proficient Model Response

The examinee's response includes four or fewer of the above responses.

Sample Case #2

Opening Scenario:

A 13-year, 8-month-old female patient presents with the chief complaint that “My teeth are not straight.”

Sample Case #2

Question 1

Classification

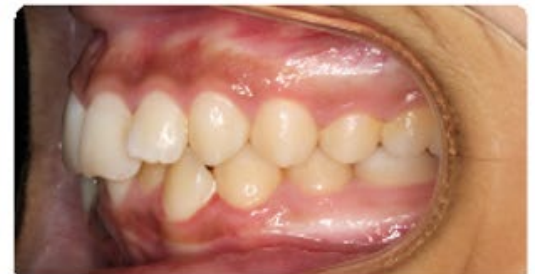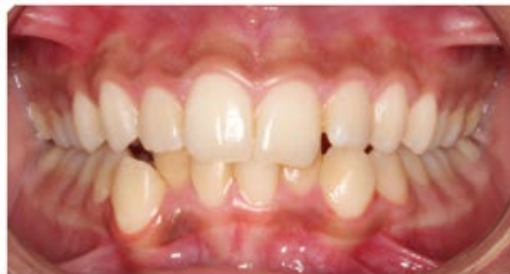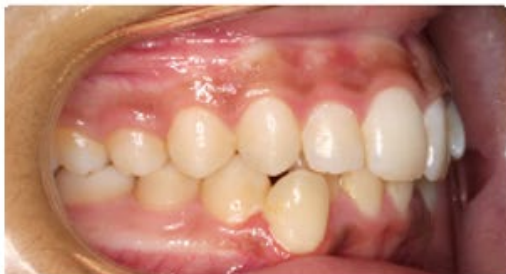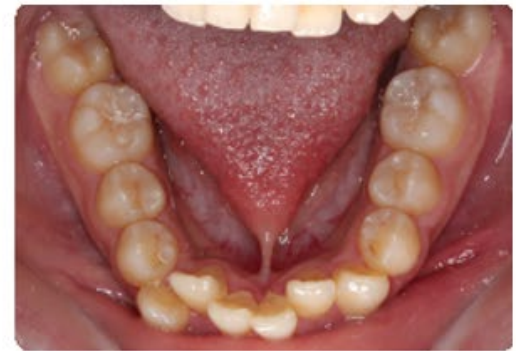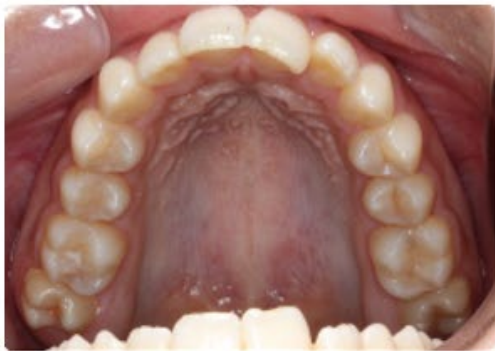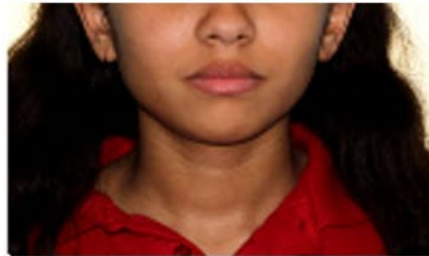Domain 2: Treatment Objectives and Planning

Prompt

Identify treatment objectives for the maxillary and mandibular incisors. Please list in bullet point format below.

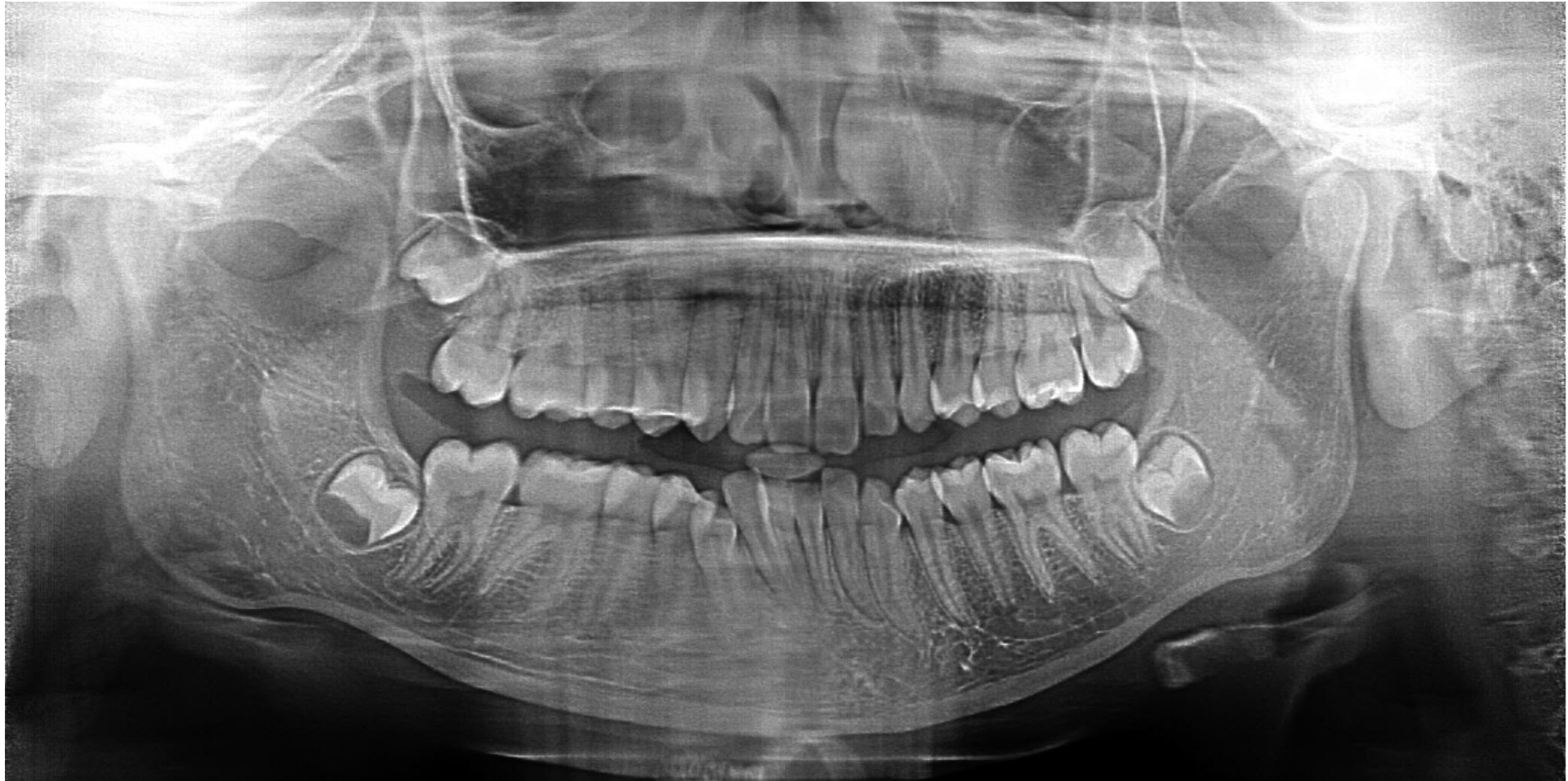Sample Case #2

Question 1



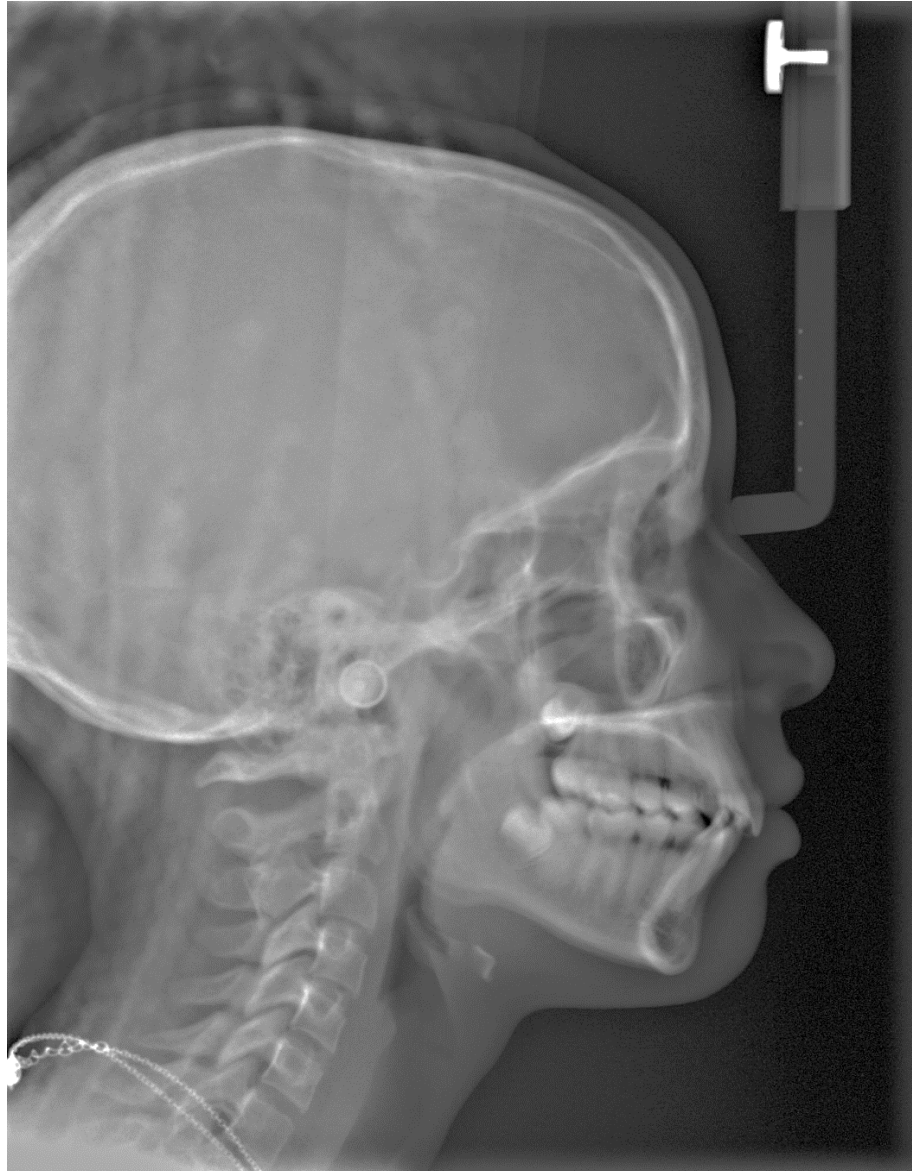
Sample Case #2

Question 1



Sample Case #2

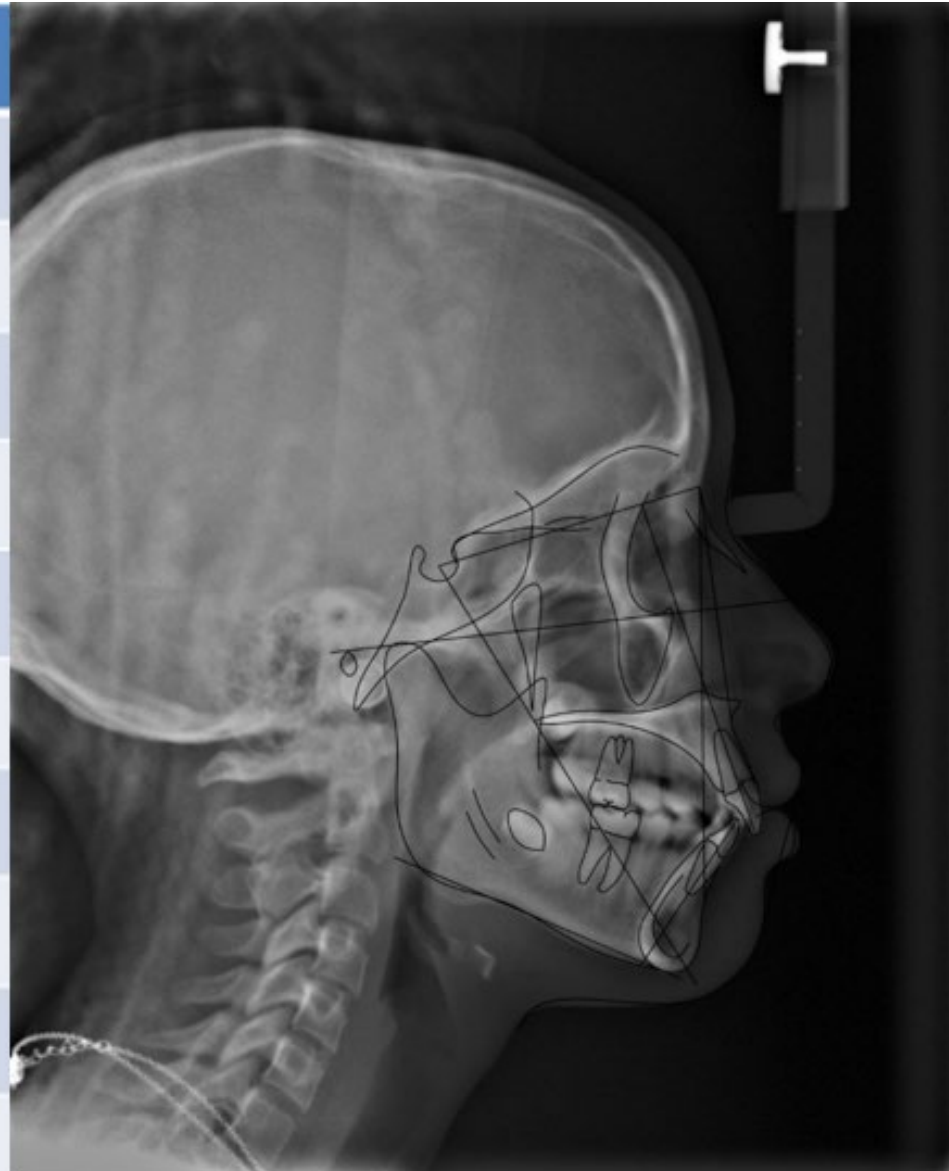Question 1



Sample Case #2

Question 1

Measure	Value
SNA	80.6
SNB	73.9
ANB	7.6
Wits	2.8
FMA	27.7
Sn-GoGn	34.2
U1-SN	100.0
IMPA	105.5
Upper lip	-0.4
Lower lip	2.7



Sample Case #2

Question 1

Fully Proficient Model Response

The examinee's response must include five of the following:

- Retract the maxillary incisors
- Control maxillary incisor torque
- Minimize vertical changes to maxillary incisors
- Retract the mandibular incisors
- Control mandibular incisor torque
- Intrude mandibular incisors (level curve of Spee)
- Correct the mandibular dental midline to the left

Sample Case #2

Question 1

Borderline Proficient Model Response

The examinee's response must include four of the above responses.

Not Proficient Model Response

The examinee's response includes three or less of the above responses.