

Scenario-based Clinical Examination

Sample Cases (Rev. 7.29.21)



The highest commitment to excellence.

Disclaimer

- The following sample questions and answers were composed and vetted by a panel of experts in orthodontics and are intended to provide an example of the types of cases and questions that make up the actual scenario-based clinical examination.
- After the examination, trained examiners, who are all board certified orthodontists, will score the typed responses using rubrics as guides to their decision making.
- Rubrics help to create consistency in the decisions the examiners make while grading an examinees typed responses. The rubrics are not absolute, as there may be other acceptable answers that are not listed.

Disclaimer Continued

- The ABO has developed multiple versions of the case-based scenario examination to be used during a test administration cycle. Although the set of cases and questions used on the different versions will not all be the same, all versions follow the same content framework as defined by the practice analysis study.
- Scores will be computed using equating procedures to ensure that all versions are of the same difficulty.
- Review of these sample cases does not guarantee that a candidate will pass the examination.
- Examinee responses to exam questions will be typed out and should be in numbered list format (i.e., short and concise, no essay responses).

Sample Case #1



The highest commitment to excellence.

Sample Case #1

Opening Scenario:

A 10-year, 8-month-old female has been referred by a dentist for an orthodontic evaluation. The mother's chief complaint is that her daughter "doesn't have room for all of her teeth."

Sample Case #1

Question 1

Classification

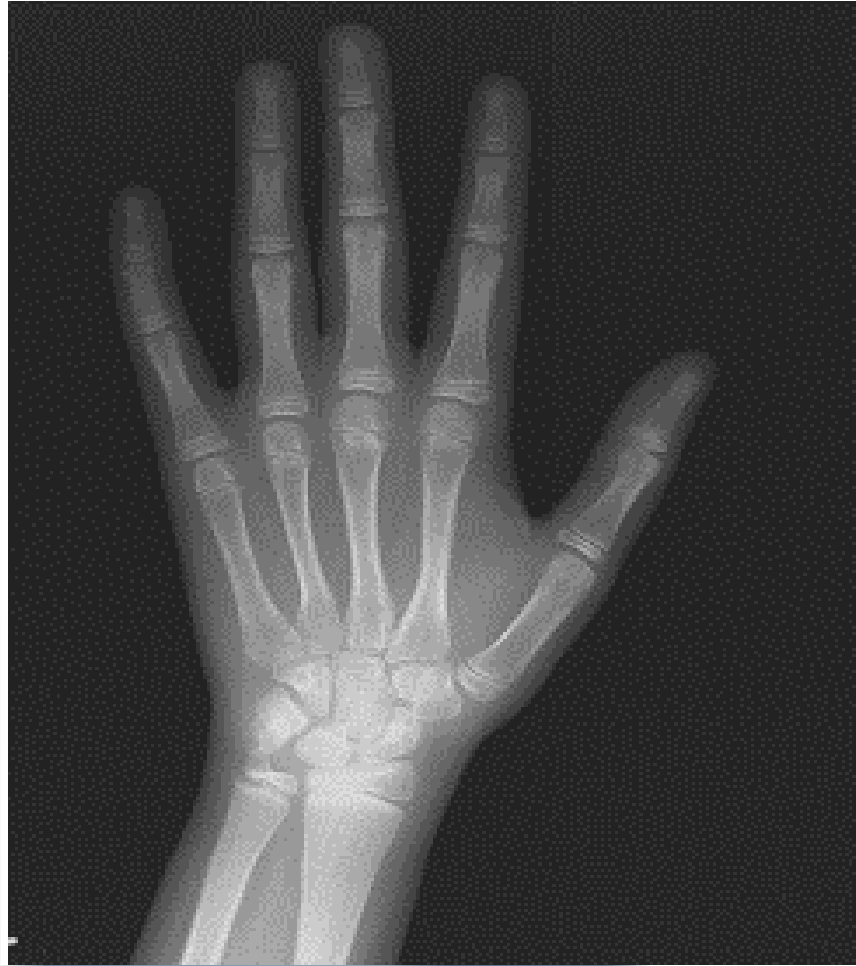Domain 1: Data Gathering and Diagnosis

Prompt

Assess the skeletal maturation of this patient and determine the skeletal maturity from those indicators. Please list in numbered format below.

Sample Case #1

Question 1



Sample Case #1

Question 1

A proficient response may include:

1. Width of epiphysis equal in width to diaphysis
2. Lack of presence of the adductor sesamoid
3. Lack of epiphyseal capping
4. Lack of epiphyseal fusion
5. Evaluation of skeletal maturation indicators suggest patient is at level 3-4, approaching peak velocity of growth -significant growth remaining

Sample Case #1

Question 2

Classification

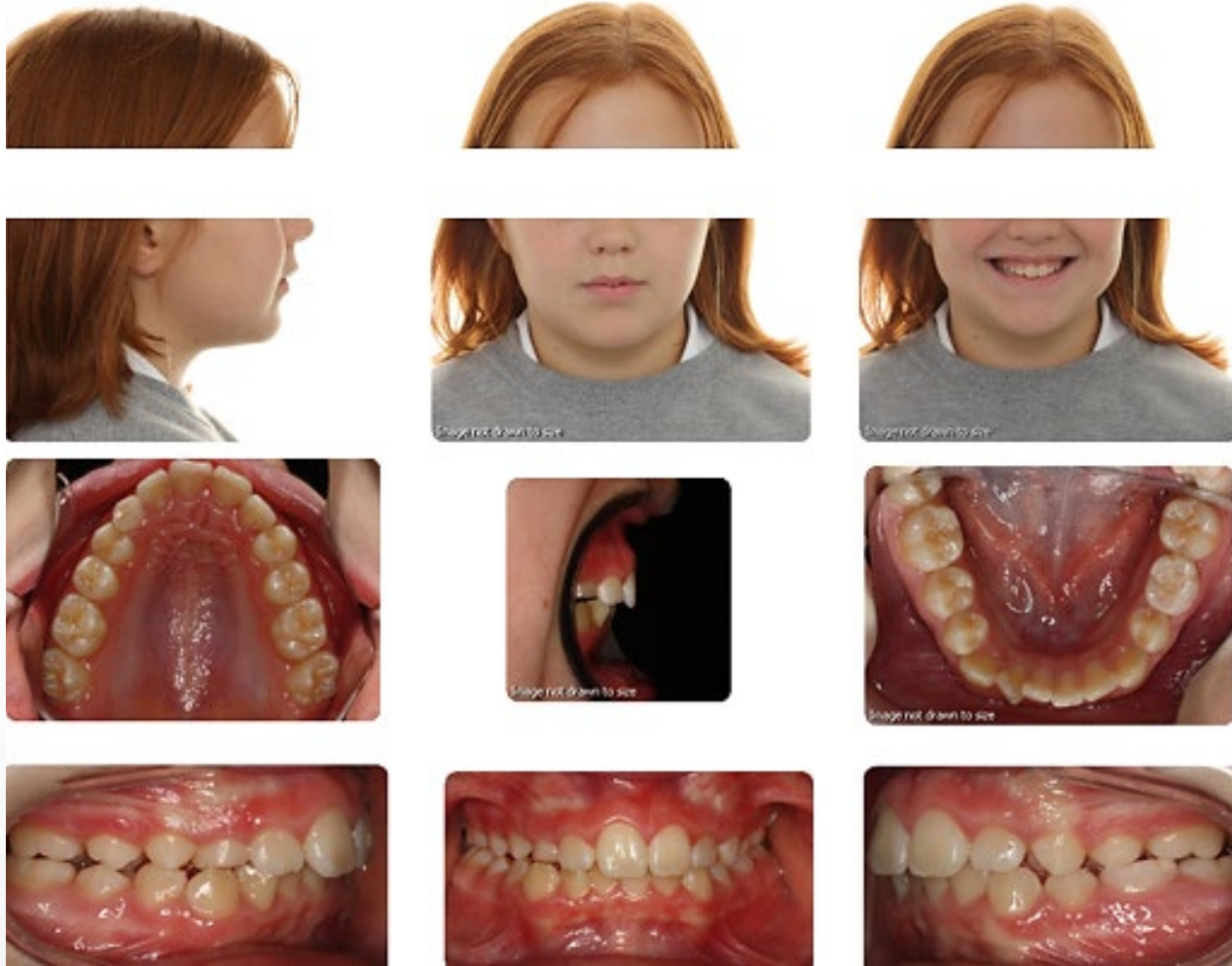Domain 2: Treatment Objectives and Planning

Prompt

Provided that the crowding in the maxillary arch will be corrected with maxillary expansion and extraction of first premolars, describe how the mandibular crowding could be resolved without compromising the facial profile. Please list in numbered format below.

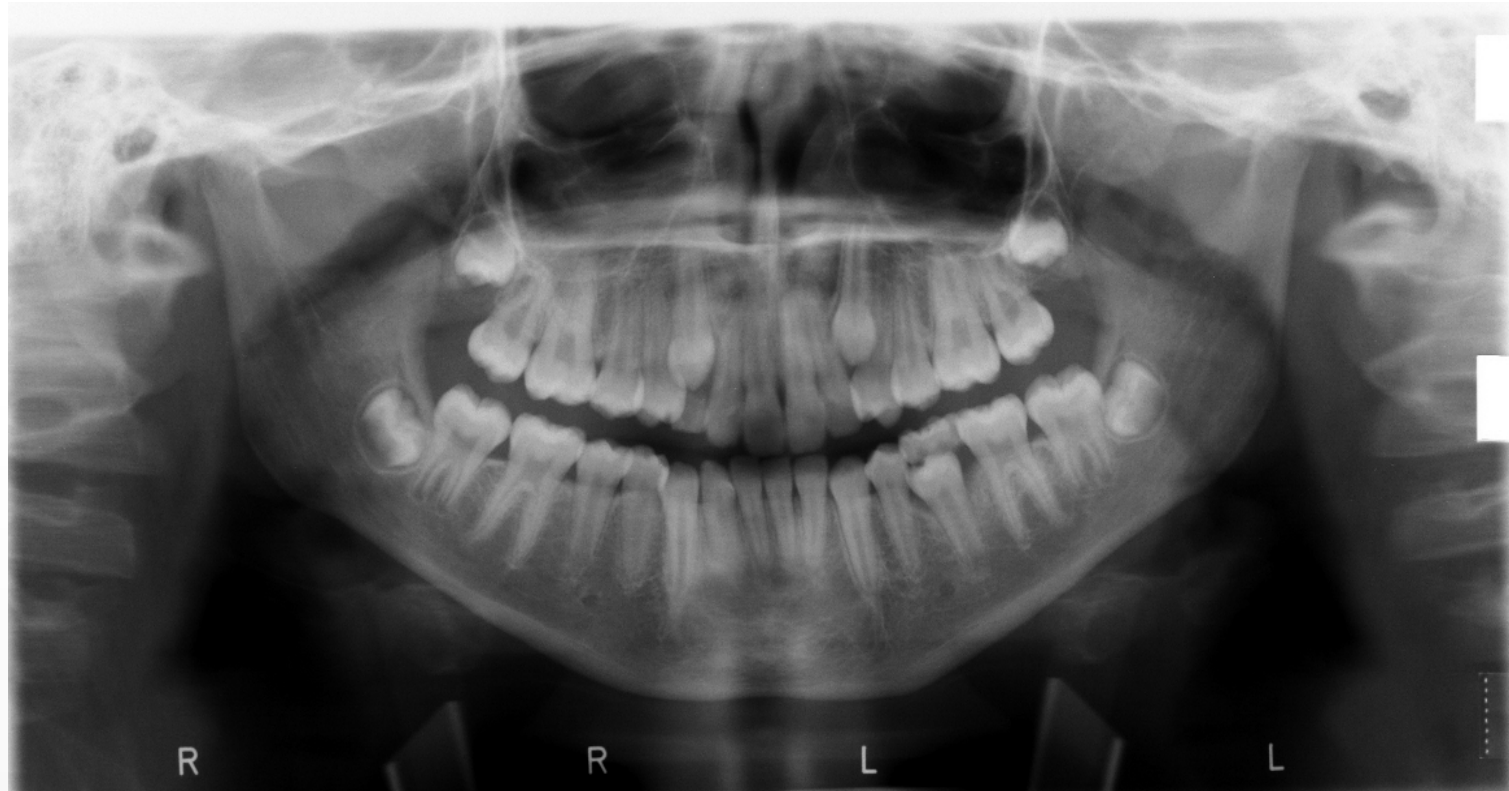Sample Case #1

Question 2



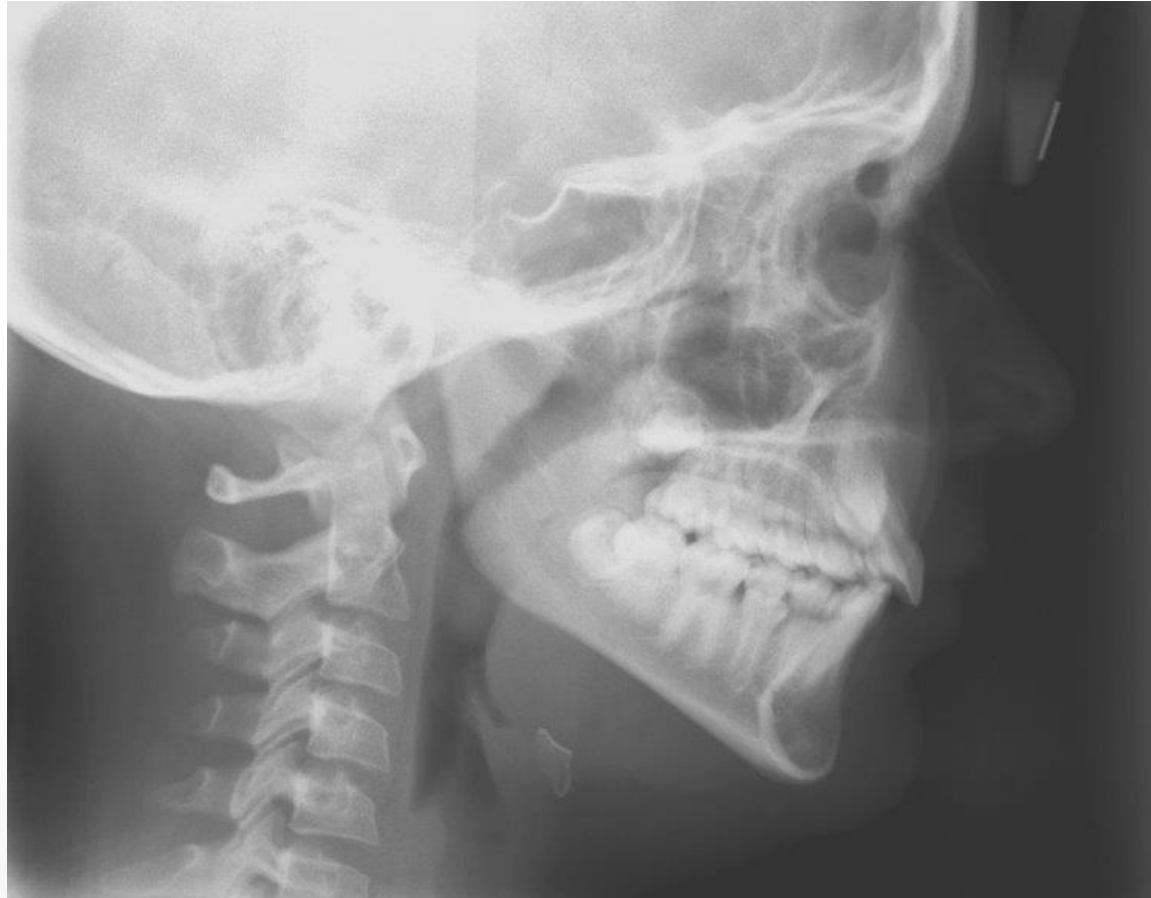Sample Case #1

Question 2



Sample Case #1

Question 2



Sample Case #1

Question 2

A proficient response might include:

1. Non extraction in the mandibular arch
2. Maintaining the leeway space on mandibular left deciduous second molar
3. Maximum anchorage on mandibular molars to move mandibular anterior teeth to the left and left canine and premolars distally
4. IPR on anterior teeth as needed

Possible acceptance response:

- Non extraction treatment with any of the following:
 - IPR
 - LLHA
 - Stopped flush arch wire
- ➡ Must include preservation of leeway space (LL E)
- ➡ Must be a non-extraction treatment in the mandibular arch

Sample Case #1

Question 3

Classification

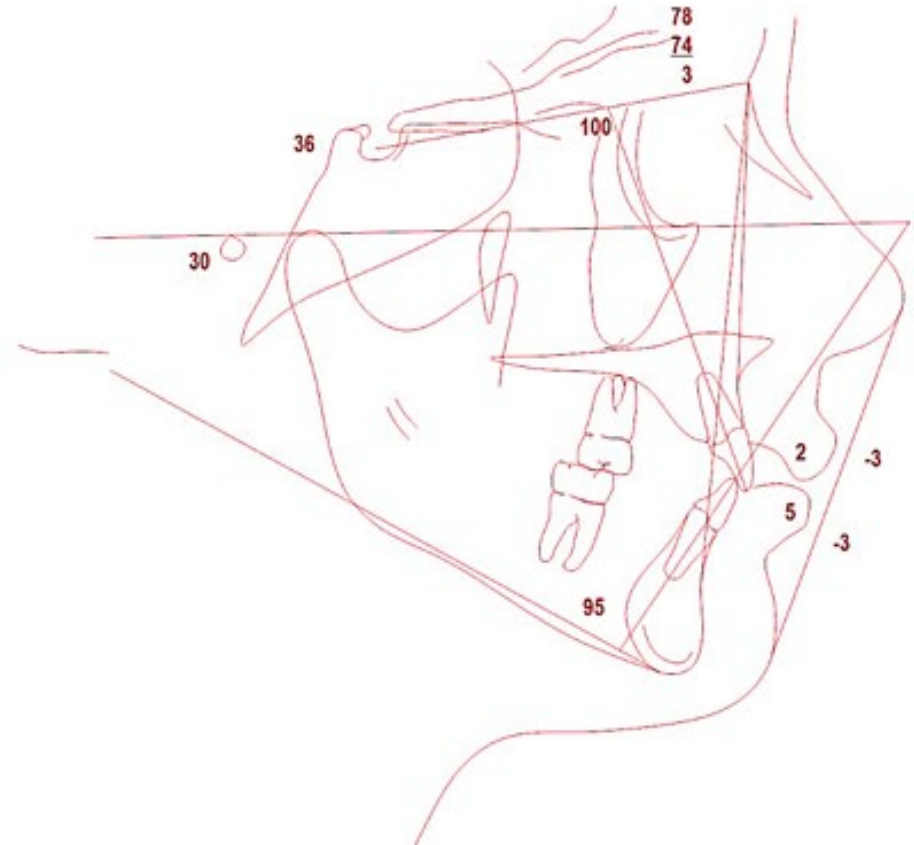
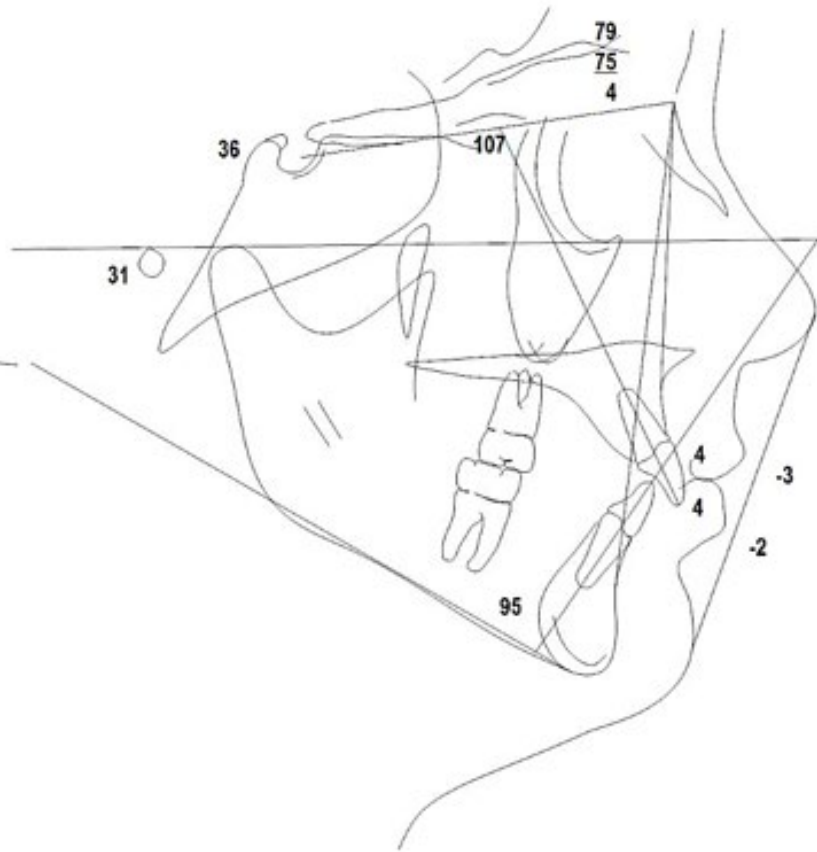
Domain 4: Critical Analysis and Outcomes Assessment

Prompt

Using the superimpositions, identify the hard tissue changes that resulted from growth and those that resulted from treatment (22 months treatment time). Please list in numbered format below.

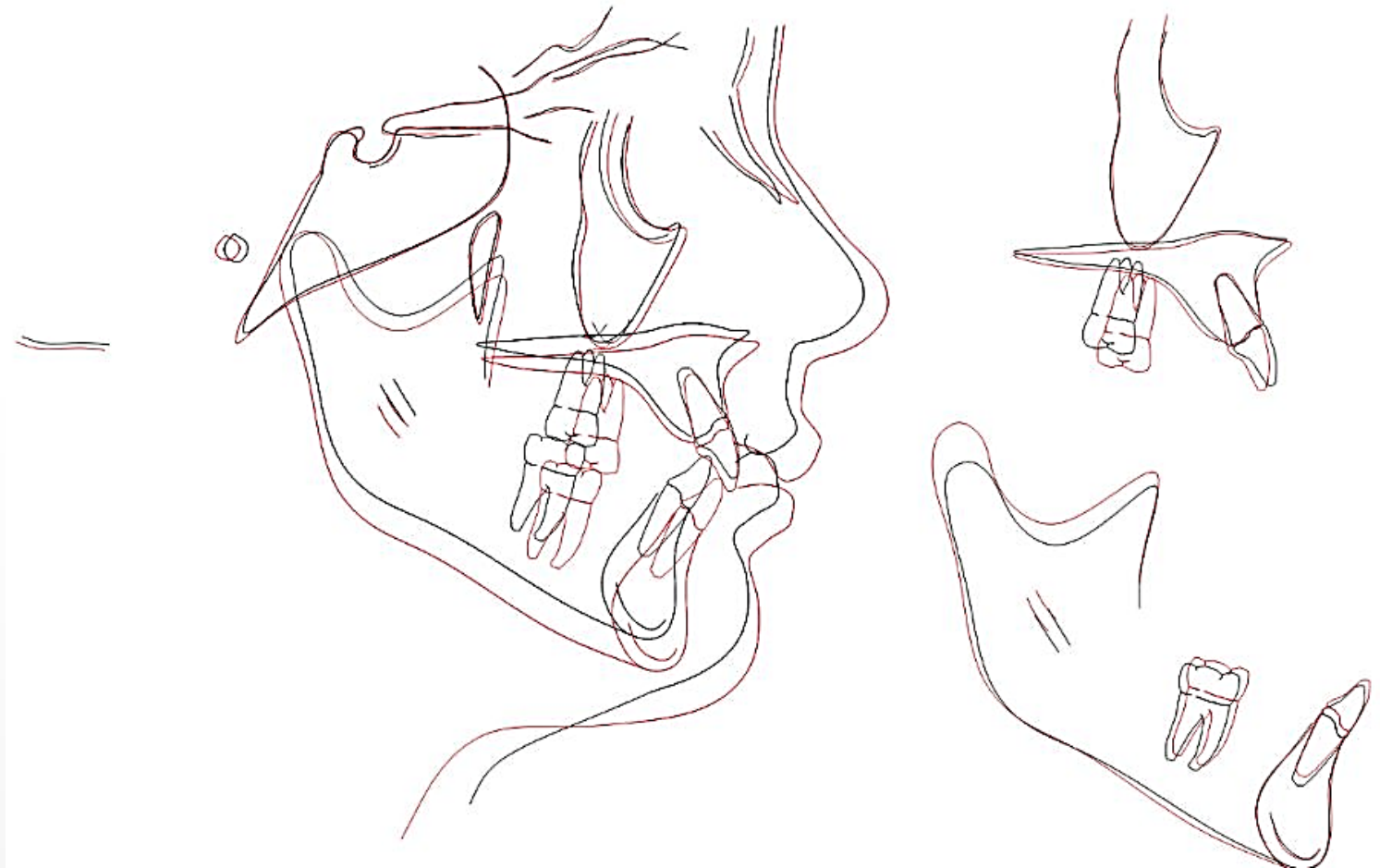
Sample Case #1

Question 3



Sample Case #1

Question 3



Sample Case #1

Question 3

A proficient response may include:

- Maxilla
 - a. Vertical change was the result of growth
 - b. Retracted at A point due to treatment
- Mandible
 - a. Pogonion (the chin) was displaced inferiorly and anteriorly due to growth
- Maxillary Molars
 - a. Moved mesially more than expected from growth
 - b. Erupted with growth and extruded slightly more than would have been expected from normal growth

Sample Case #1

Question 3 (Continued)

- Maxillary incisors
 - a. Retracted due to treatment
 - b. Held vertically due to treatment
- Mandibular molars
 - a. Erupted with growth
 - b. Moved mesial slightly with growth
 - c. Mandibular incisors moved slightly forward as a result of growth
 - d. Mandibular incisors moved vertical as expected from growth

Sample Case #2



The highest commitment to excellence.

Sample Case #2

Opening Scenario:

An 8-year, 10-month-old male has been referred by a dentist for an orthodontic evaluation of permanent tooth eruption. The mother's chief complaint is that "my son grinds his teeth at night."

Sample Case #2

Question 1

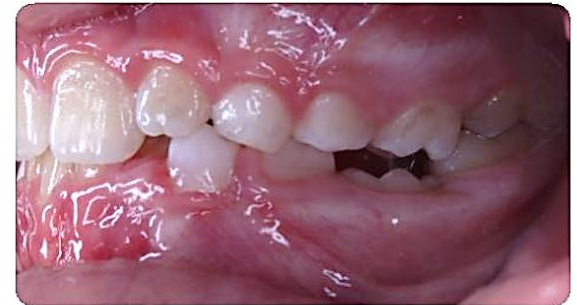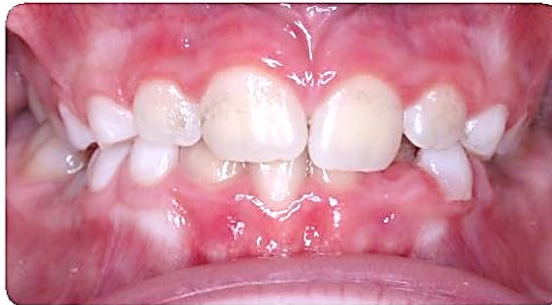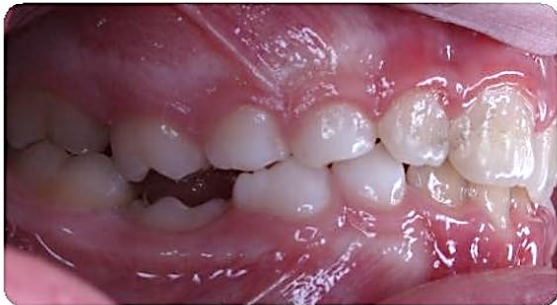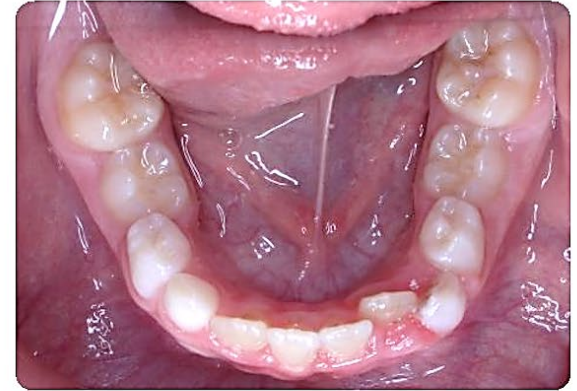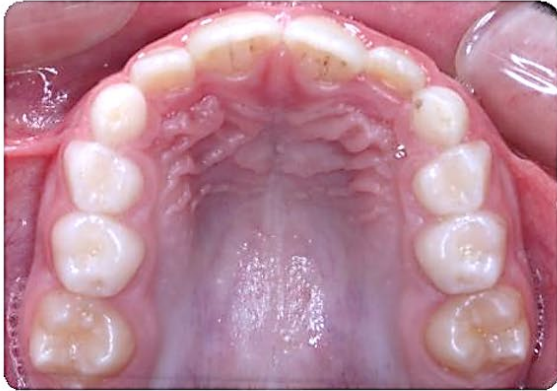Domain 1: Data Gathering and Diagnosis

Prompt

Identify all dental abnormalities evident in the intraoral photographs and the panoramic radiograph. Please list in numbered format below.

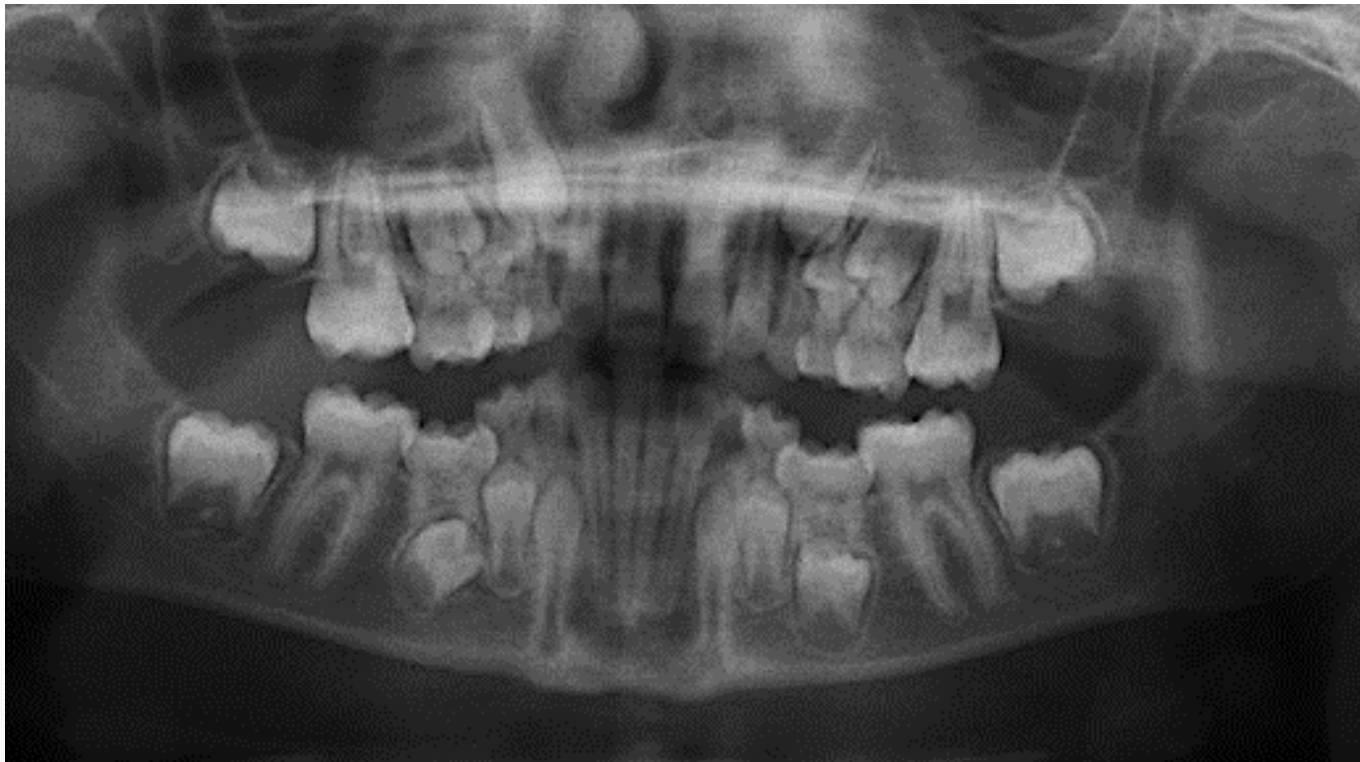Sample Case #2

Question 1



Sample Case #2

Question 1



Sample Case #2

Question 1

A proficient response may include:

1. Ankylosis of the mandibular second deciduous molars
2. Supra eruption of the maxillary second deciduous molars
3. Mesio-angulated mandibular right second premolar
4. Mesial tipping of the mandibular first molars
5. Mandibular anterior crowding with linguallly displaced left lateral incisor
6. Reduced attach gingiva on the mandibular right central incisor
7. Deep overbite

Sample Case #2

Question 2

Classification

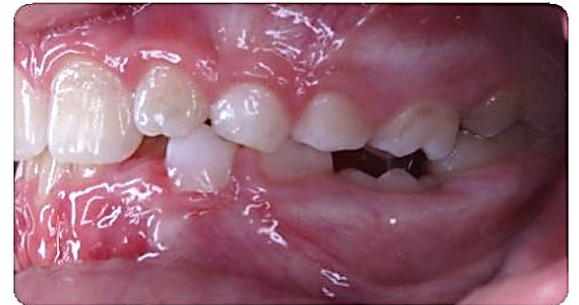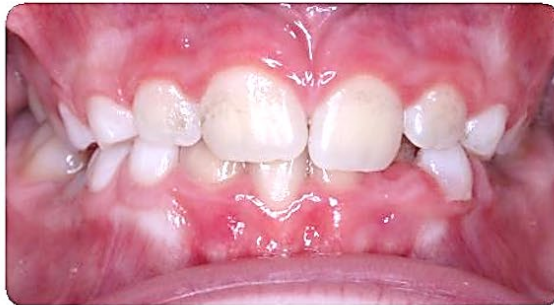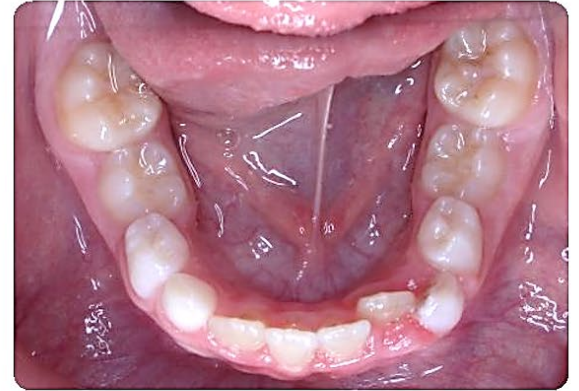Domain 2: Treatment Objectives and Planning

Prompt

List the potential complications associated with the ankylosis of the mandibular second deciduous molars. Please list in numbered format below.

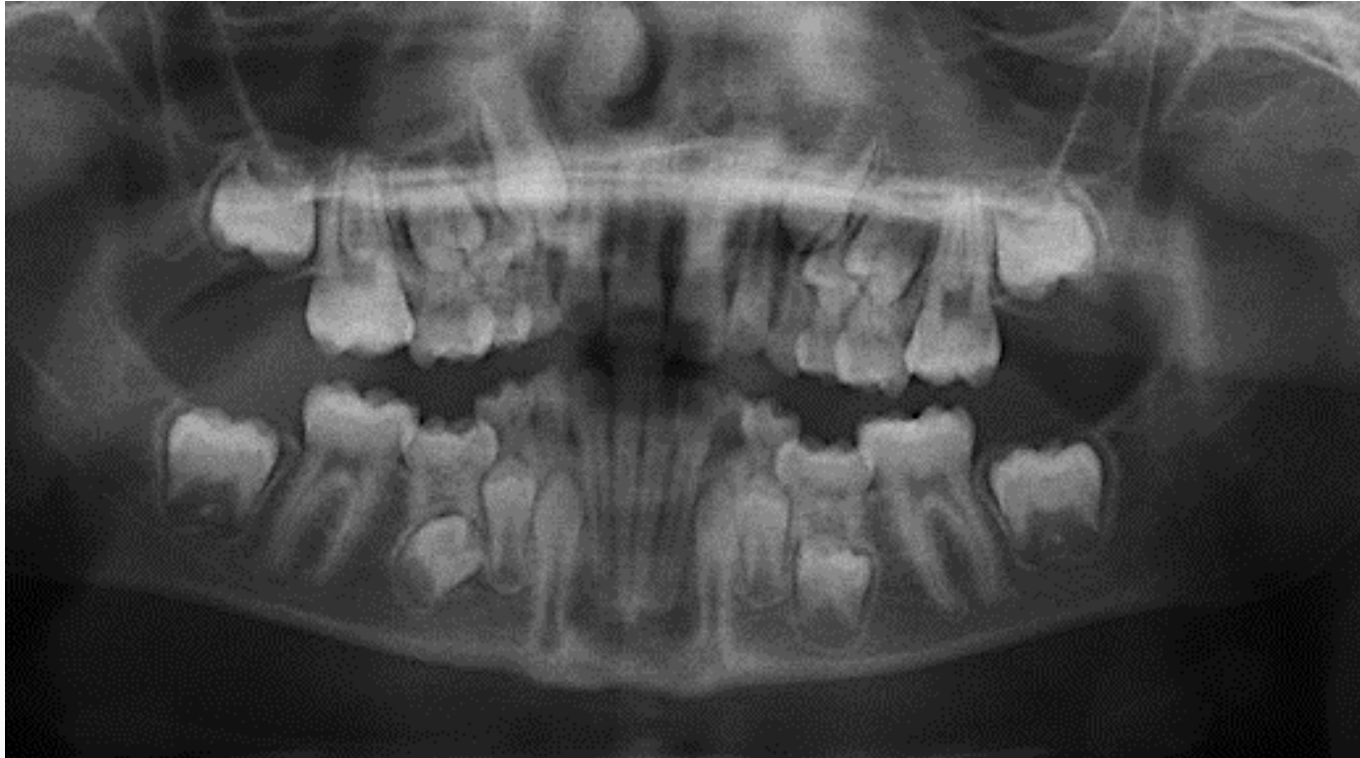Sample Case #2

Question 2



Sample Case #2

Question 2



Sample Case #2

Question 2

A proficient response may include:

1. Ectopic eruption of the mandibular second premolars
2. Tipping of adjacent teeth
3. Further submergence of the ankylosed mandibular second deciduous molars
4. Periodontal bony defect on the ankylosed teeth
5. Impaction of mandibular second premolars
6. Decreased arch length
7. Lateral open bite
8. Extruded antagonist maxillary tooth

Sample Case #3



The highest commitment to excellence.

Sample Case #3

Opening Scenario:

A 12-year, 5-month-old female presents without a chief complaint. Her dentist recommended an orthodontic consultation.

Sample Case #3

Question 1

Classification

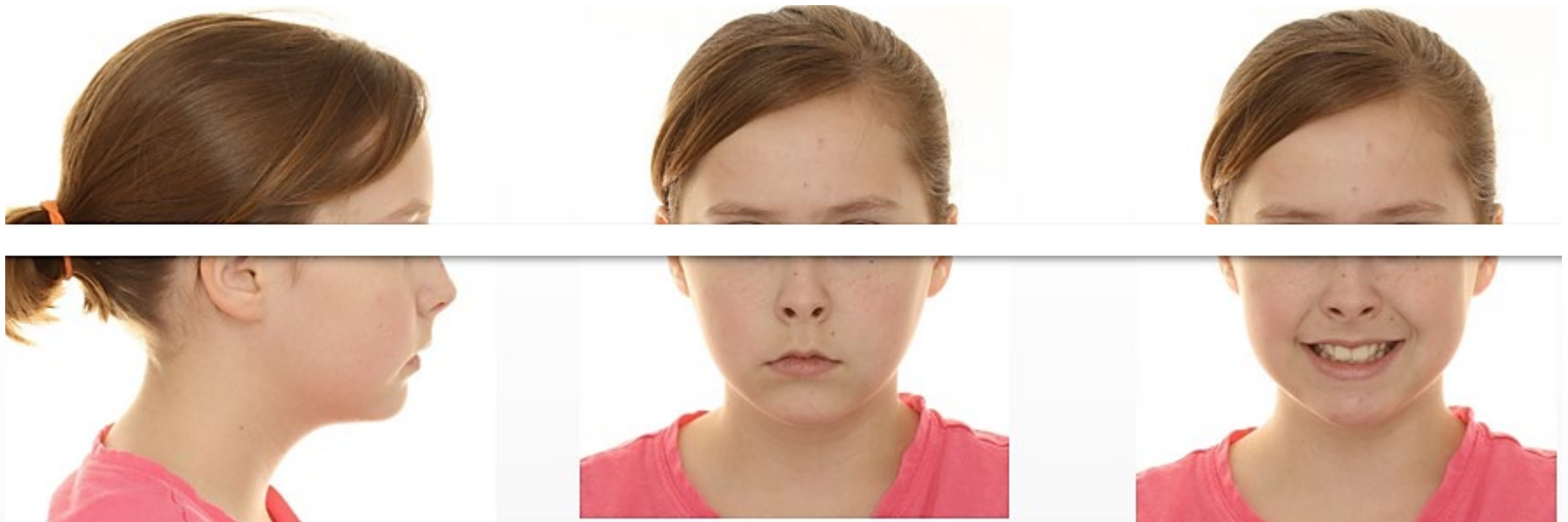Domain 1: Data Gathering and Diagnosis

Prompt

List the skeletal components of this patient's malocclusion. Please list in numbered format below.

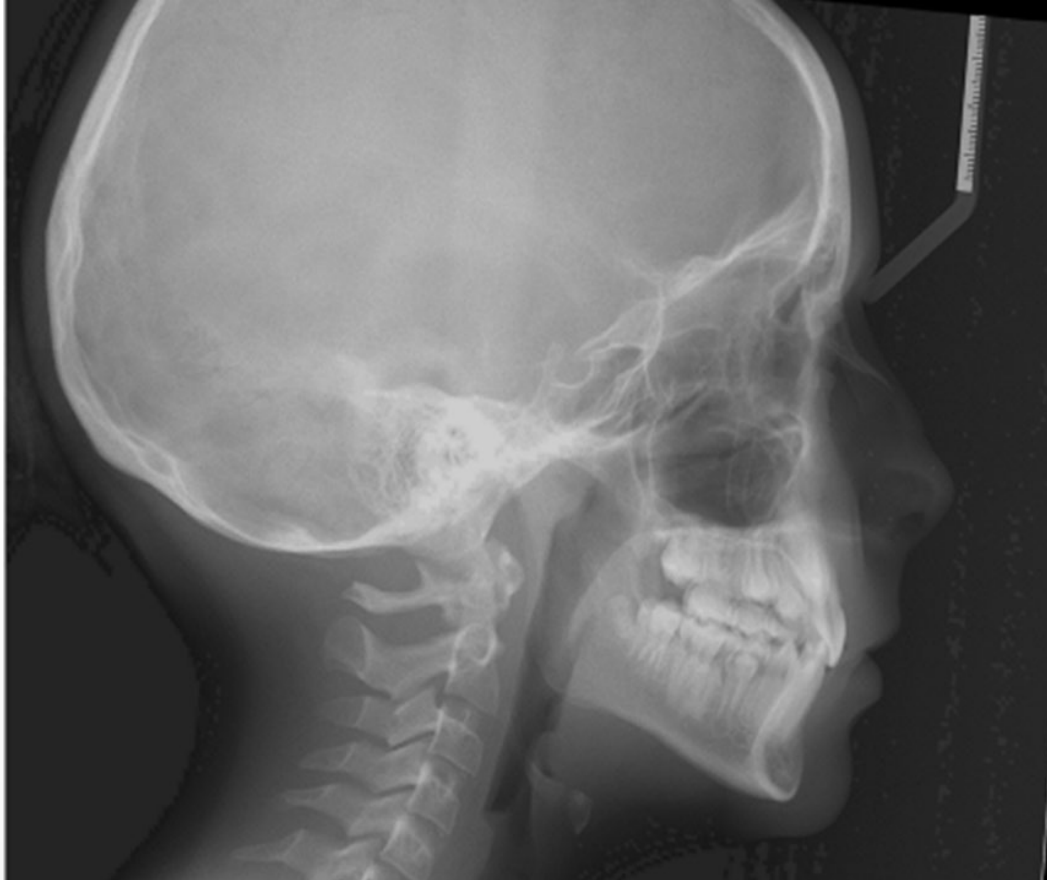Sample Case #3

Question 1



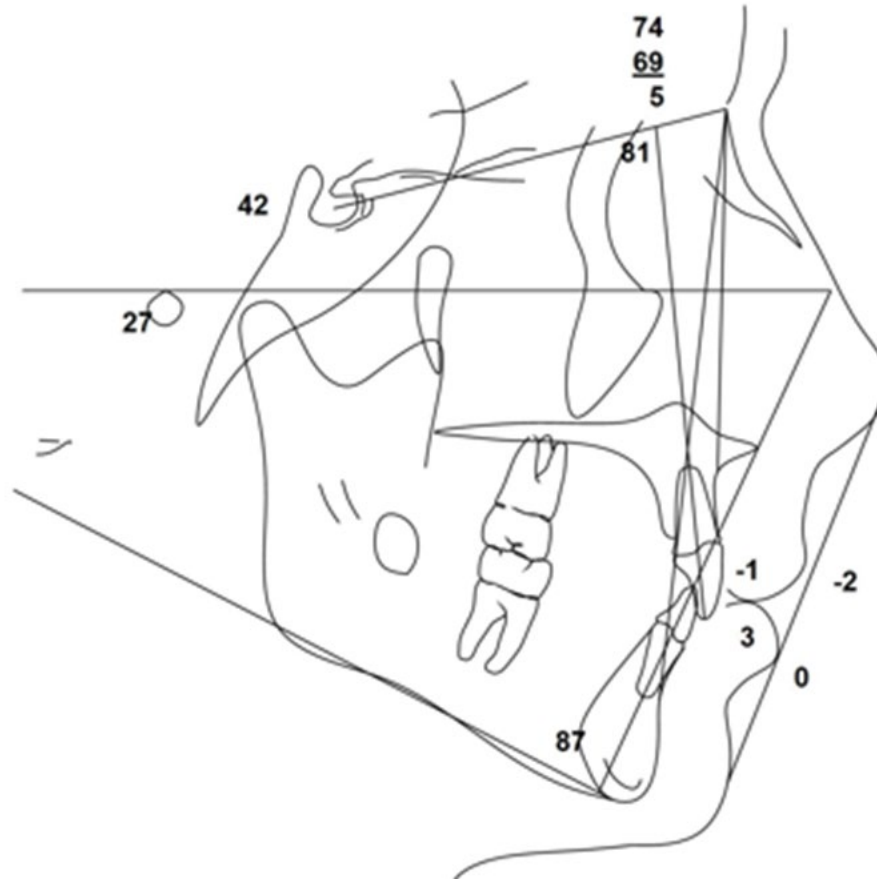
Sample Case #3

Question 1



Sample Case #3

Question 1



Sample Case #3

Question 1

A proficient response may include:

1. Steep cranial base
2. Skeletal Class II
3. Normal maxilla in AP
4. Retrusive/retrognathic mandible
5. Normodivergent (hyperdivergent tendency is also an acceptable)

Sample Case #3

Question 2

Classification

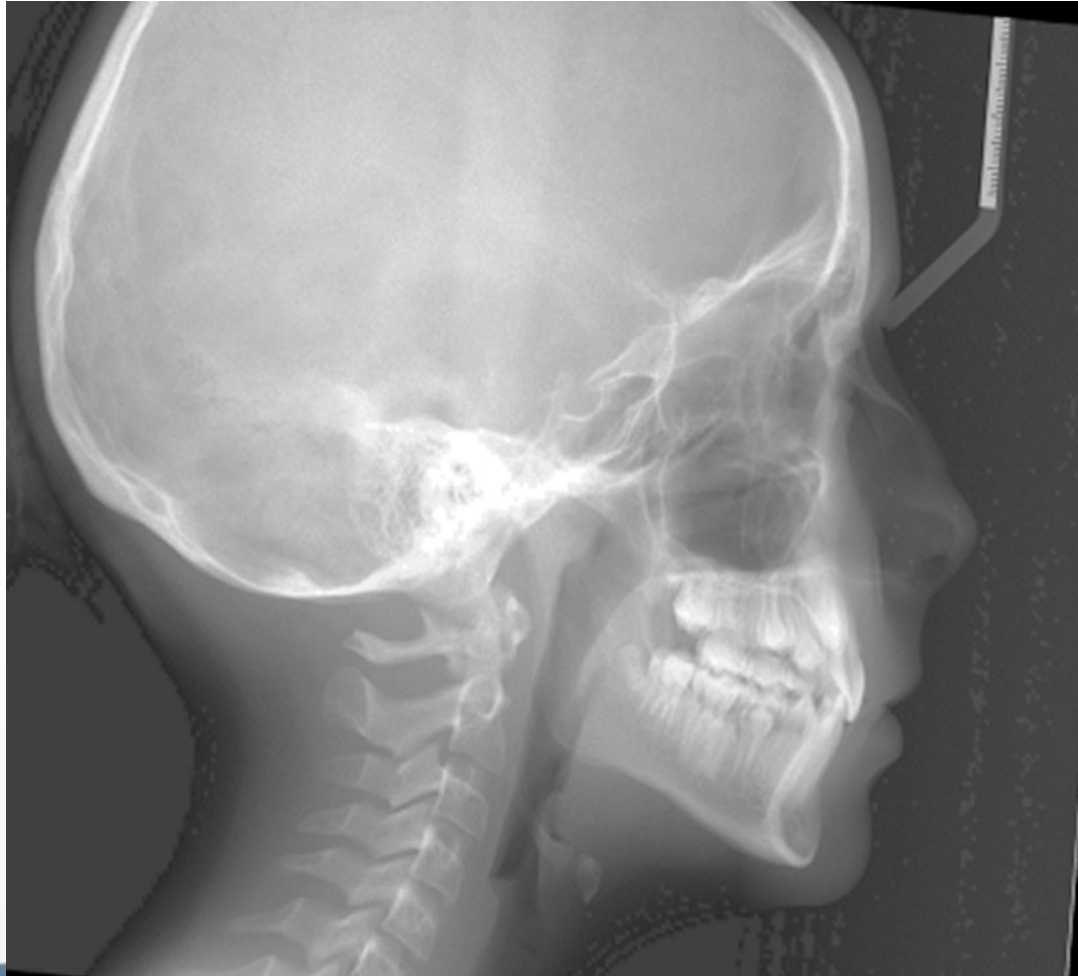Domain 2: Treatment Objectives and Planning

Prompt

Describe the patient's skeletal stage and growth potential. Please list in numbered format below.

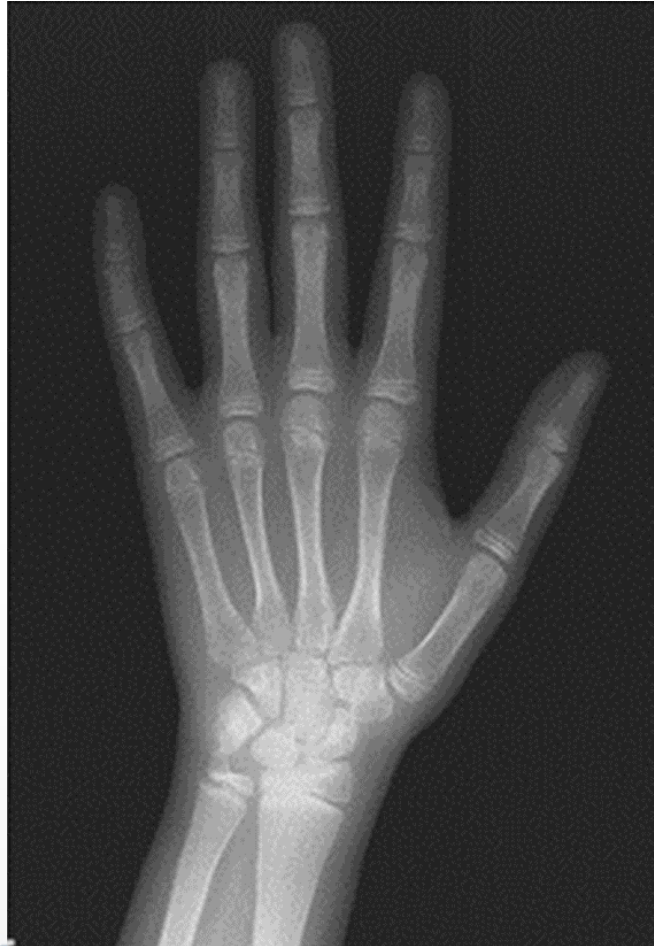Sample Case #3

Question 2



Sample Case #3

Question 2



Sample Case #3

Question 2

A proficient response may include:

1. Patient is expected to grow (1-1.5 years) based on:
 - Cervical Vertebral Maturation Stage (CVMS) is 2 (accept between 2 and 3)
 - Skeletal Maturation Indicator (SMI) is 3 to 4

NOTE: Growth potential is about 4 years, but the maximum growth would be experienced during the next 1 – 1.5 years.

Sample Case #3

Question 3

Classification

Domain 4: Critical Analysis and Outcomes Assessment

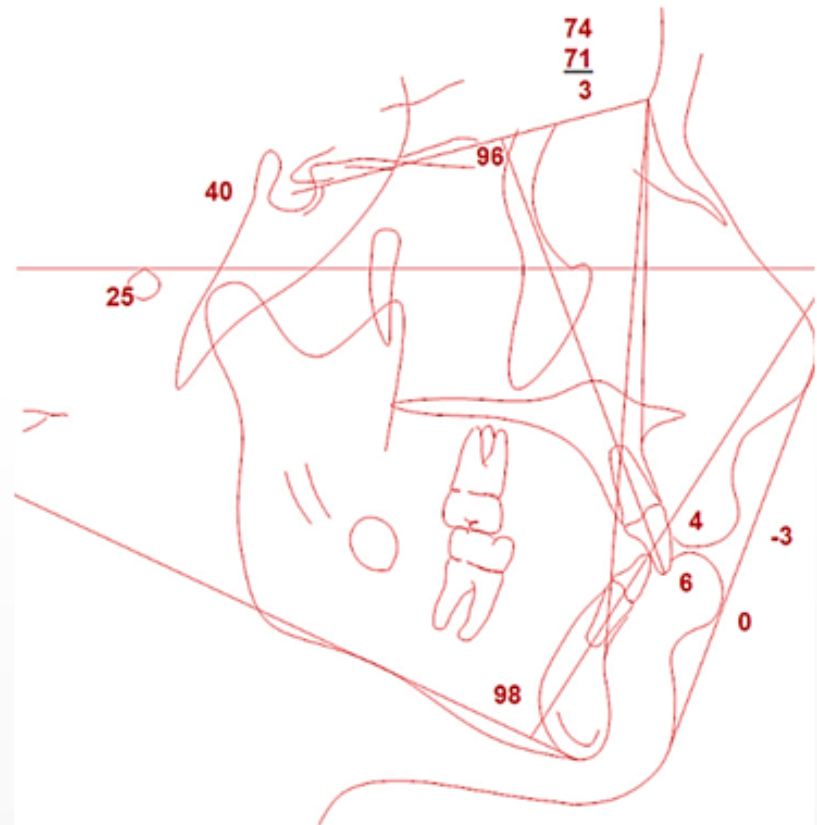
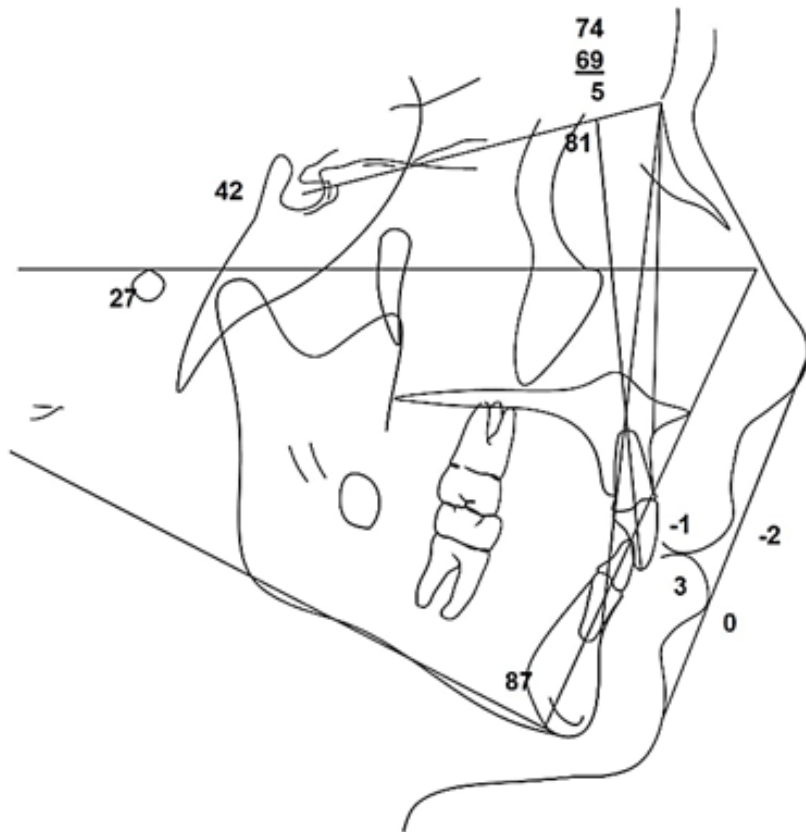
Prompt

This patient was treated with comprehensive, non extraction orthodontic treatment. The time between pre- and post-treatment records was 34 months.

What dental changes occurred as the result of treatment? Please list in numbered format below.

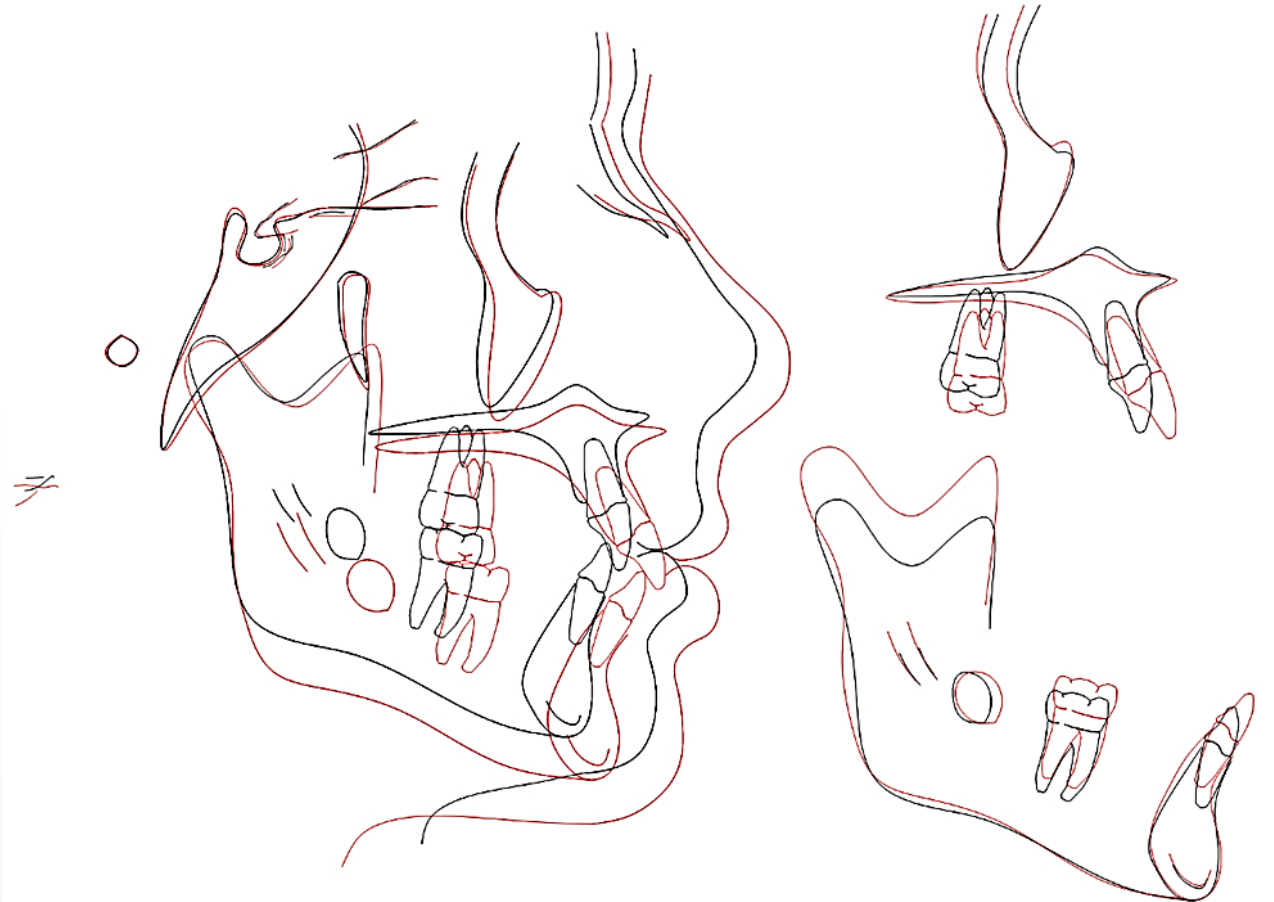
Sample Case #3

Question 3



Sample Case #3

Question 3



Sample Case #3

Question 3

A proficient response may include:

1. Maxillary incisors were proclined due to treatment
2. Mandibular incisors were proclined due to treatment
3. Maxillary first molar extruded due to treatment

NOTE: All other A-P and vertical changes in tooth position were the result of normal growth

Sample Case #4



The highest commitment to excellence.

Sample Case #4

Opening Scenario:

A 14-year, 9-month-old female presents with a chief complaint that “I don’t like my bite.”

Sample Case #4

Question 1

Classification

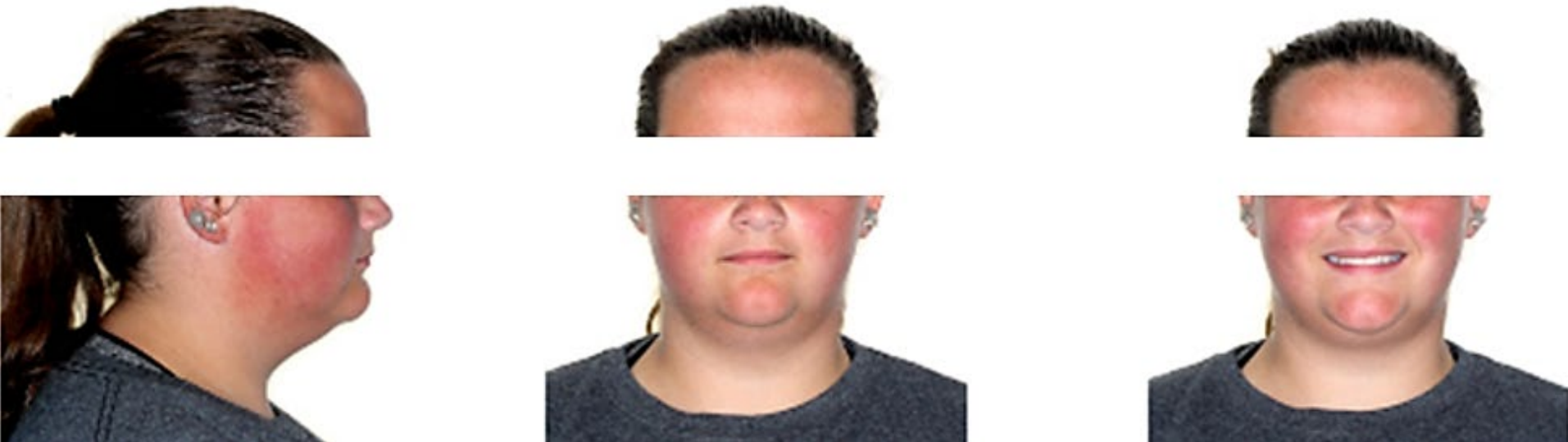Domain 1: Data Gathering and Diagnosis

Prompt

Describe the facial characteristics of this patient. Please list in numbered format below.

Sample Case 4

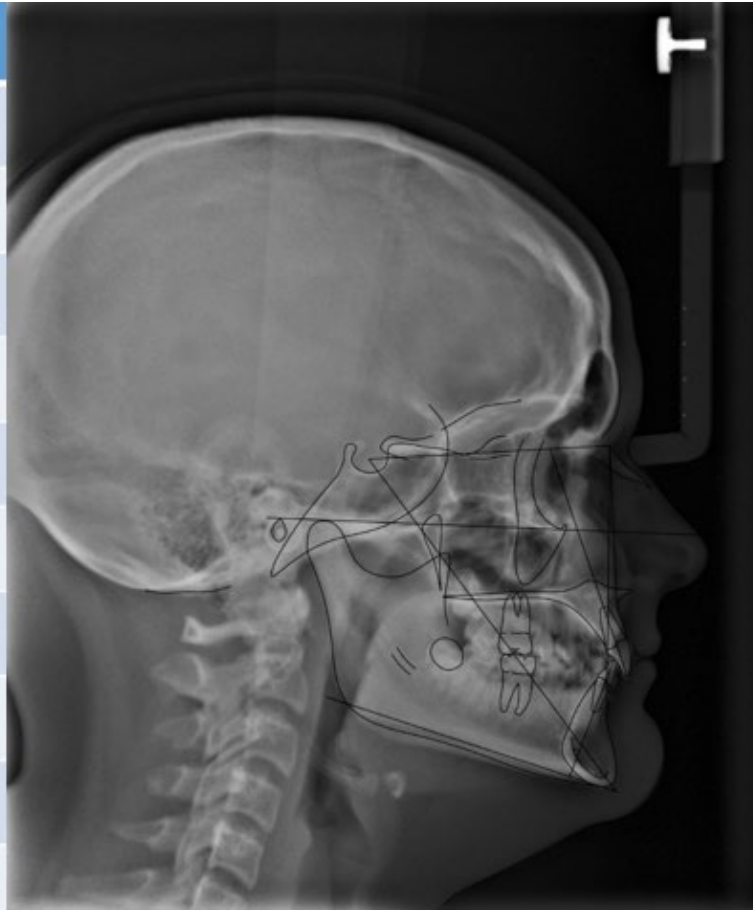
Question 1



Sample Case 4

Question 1

Measure	Value
SNA	89.4
SNB	86.1
ANB	3.2
Wits	-1.6
FMA	15.8
SN-GoGn	19.9
U1-SN	105.6
IMPA	92.6
Upper lip	-8.0
Lower lip	-7.1



Sample Case #4

Question 1

Fully Proficient Model Response

The examinee's response must include five or more of the following:

1. Straight profile
2. Prominent soft tissue pogonion
3. Deep mentolabial sulcus
4. Obtuse nasiolabial angle
5. Obtuse chin-throat angle/ Poor chin-neck contour
6. Deficient vermillion display
7. Thin lips

Sample Case #4

Question 1

Borderline Proficient Model Response

The examinee's response must include four of the above responses.

Not Proficient Model Response

The examinee's response includes three or fewer of the above responses.

Sample Case #5



The highest commitment to excellence.

Sample Case #5

Opening Scenario:

A 13-year, 8-month-old female patient presents with the chief complaint that “My teeth are not straight.”

Sample Case #5

Question 1

Classification

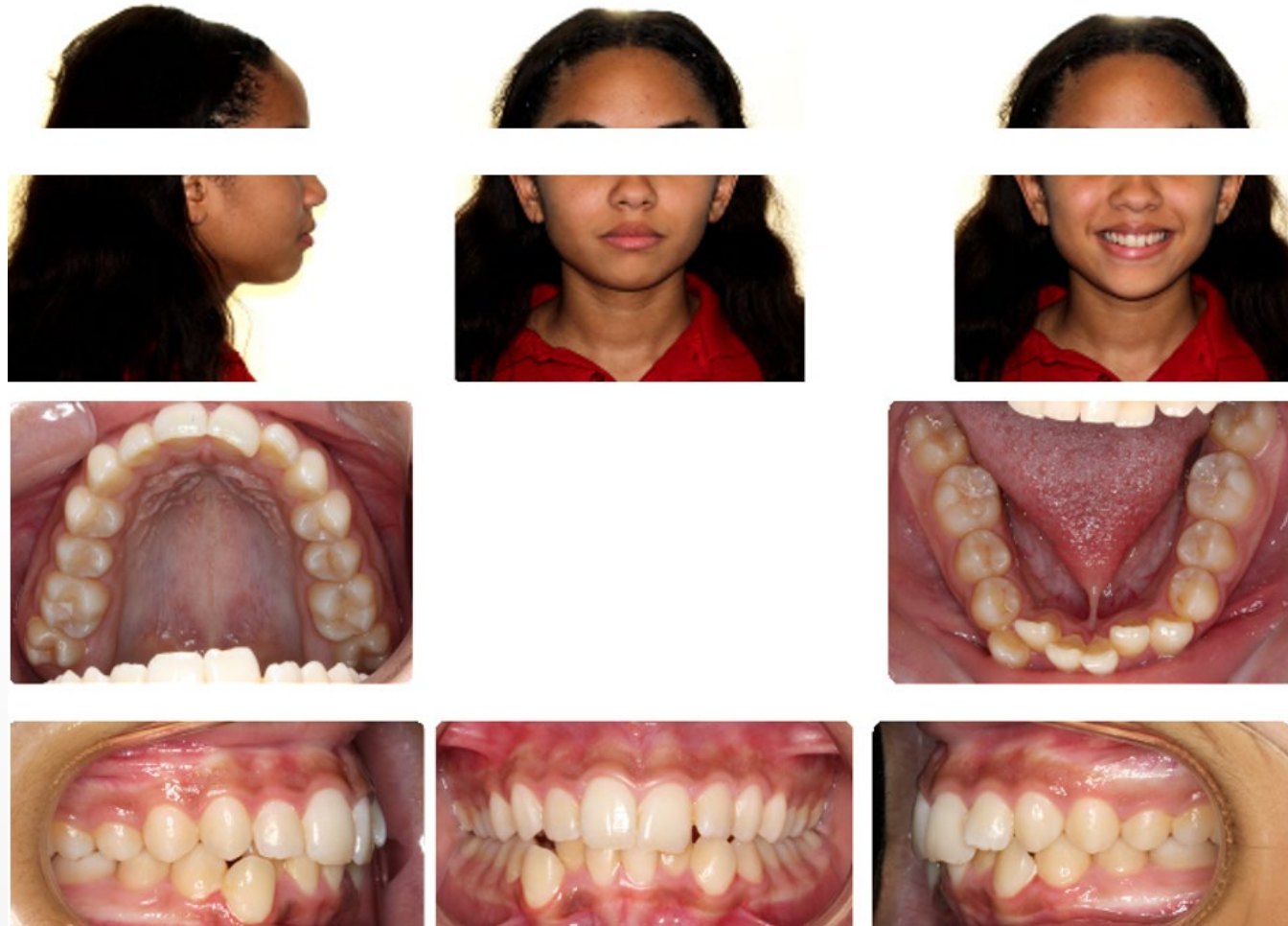
Domain 2: Treatment Objectives and Planning

Prompt

Identify treatment objectives for the maxillary and mandibular incisors.
Please list in numbered format below.

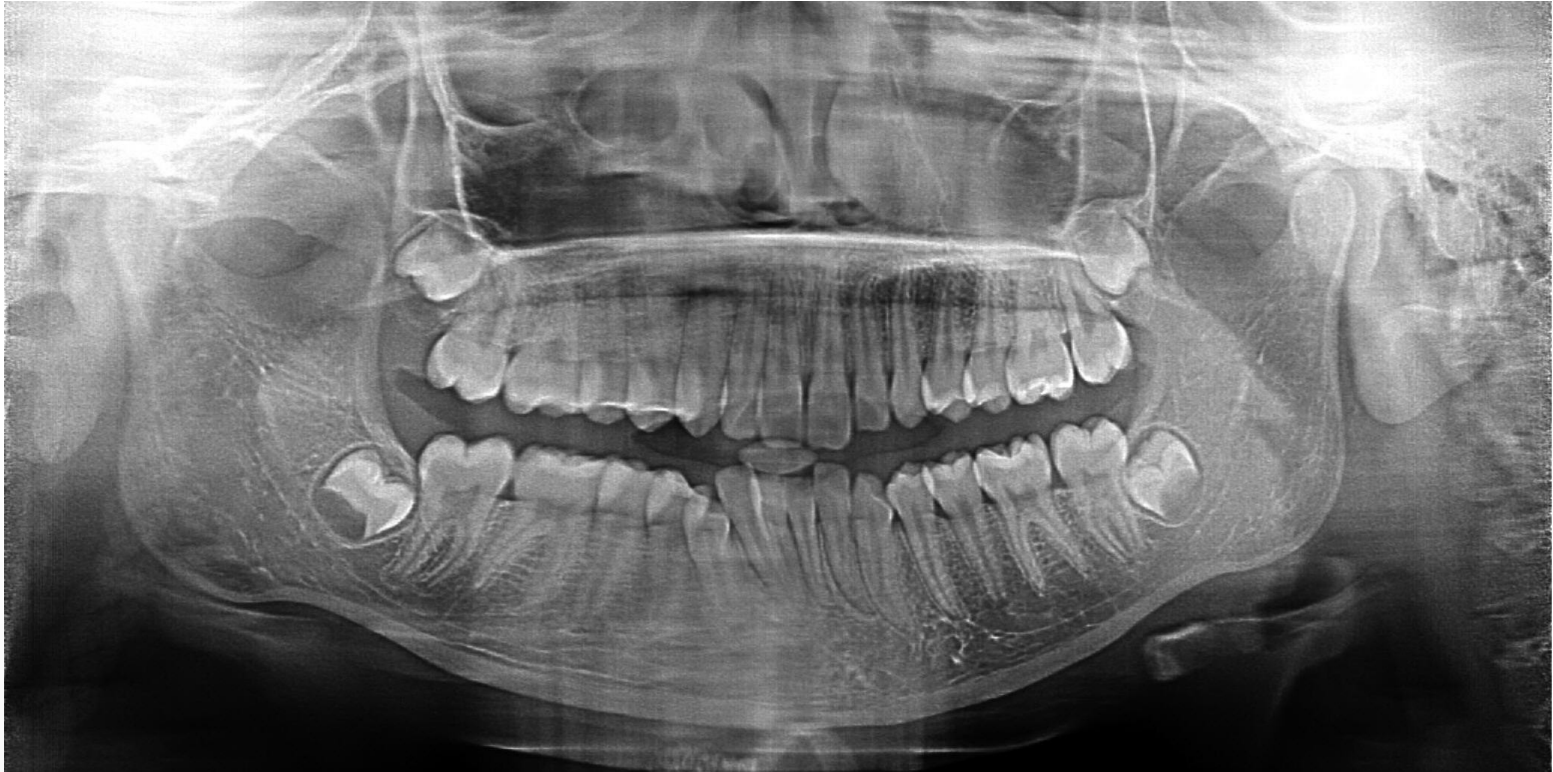Sample Case #5

Question 1



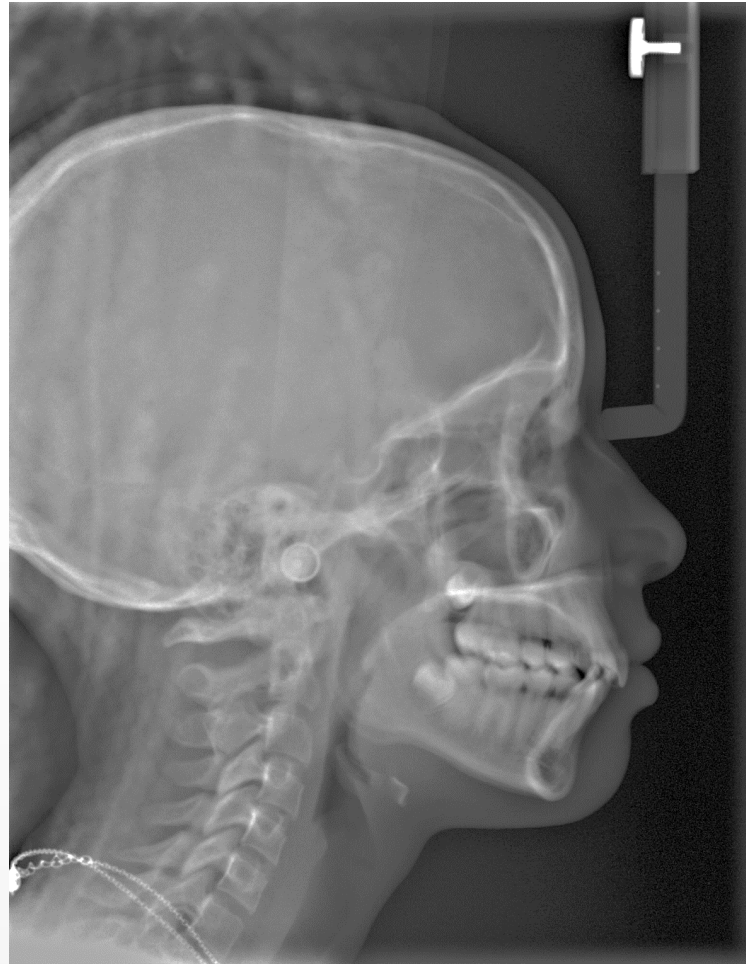
Sample Case #5

Question 1



Sample Case #5

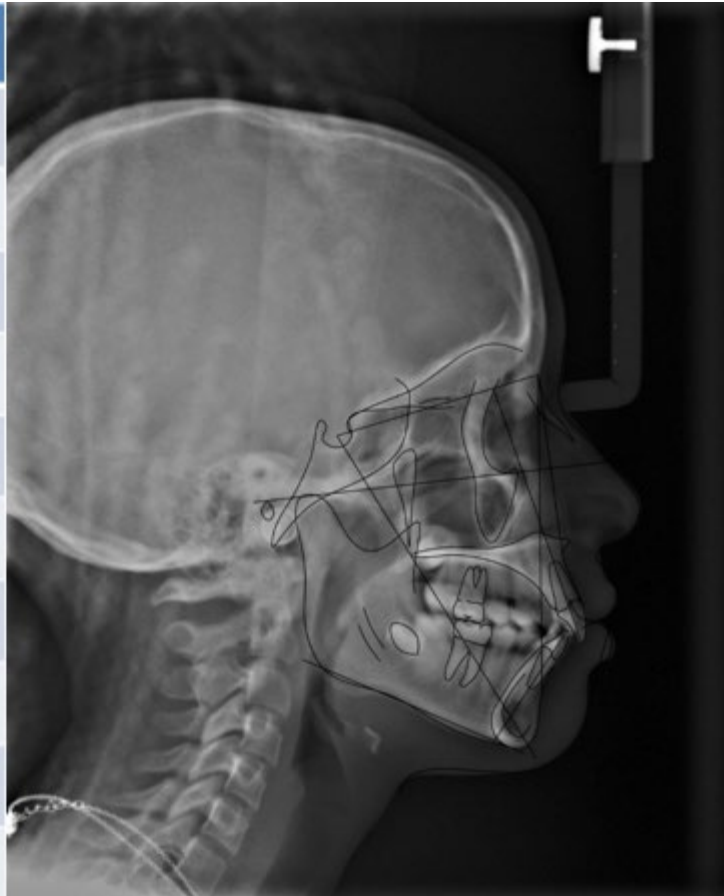Question 1



Sample Case #5

Question 1

Measure	Value
SNA	80.6
SNB	73.9
ANB	7.6
Wits	2.8
FMA	27.7
Sn-GoGn	34.2
U1-SN	100.0
IMPA	105.5
Upper lip	-0.4
Lower lip	2.7



Sample Case #5

Question 1

Fully Proficient Model Response

The examinee's response must include five of the following:

1. Retract the maxillary incisors
2. Control maxillary incisor torque
3. Minimize vertical changes to maxillary incisors
4. Retrocline mandibular incisors
5. Control mandibular incisor torque
6. Intrude mandibular incisors (level curve of spee)
7. Correct the mandibular dental midline

Sample Case #5

Question 1

Borderline Proficient Model Response

The examinee's response **must** include four of the above responses.

Not Proficient Model Response

The examinee's response includes three or fewer of the above responses.

Mock Board Exam

Sample Case #6



The highest commitment to excellence.

Sample Case #6

Opening Scenario:

A 15-year, 2-month-old female presents with crowding and an open bite. The patient's chief complaint is that "my teeth are ugly."

Sample Case #6

Question 1

Classification

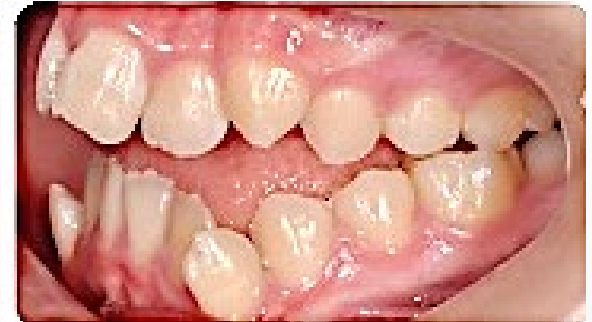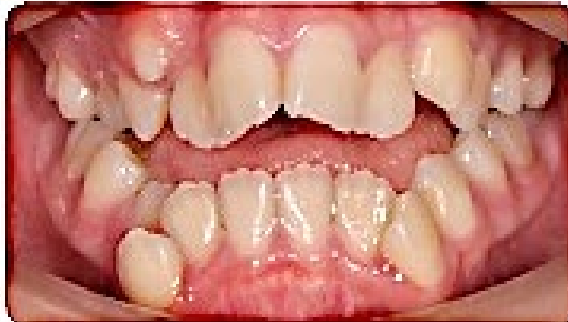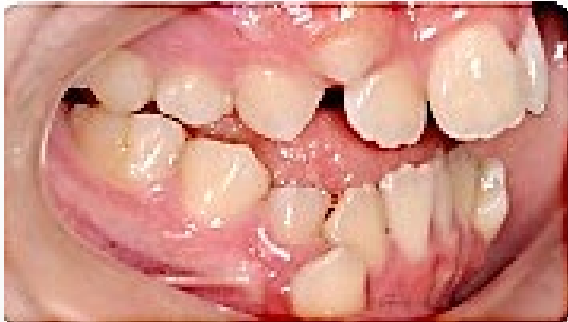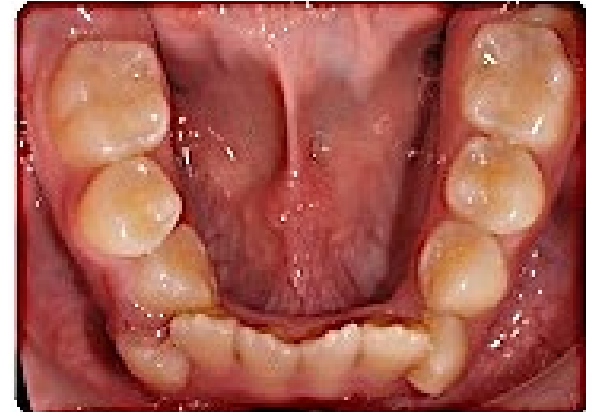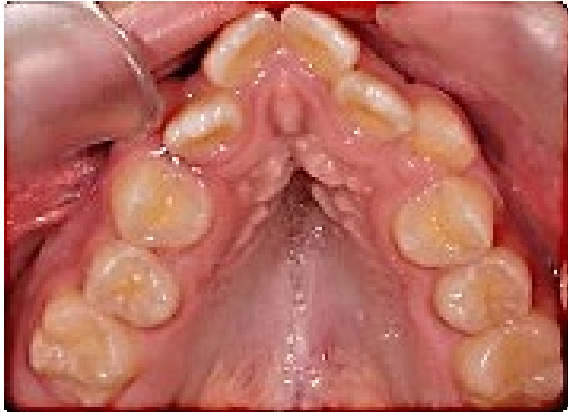Domain 1: Data Gathering and Diagnosis

Prompt

List the skeletal components of this patient's open bite. Please list in numbered format below.

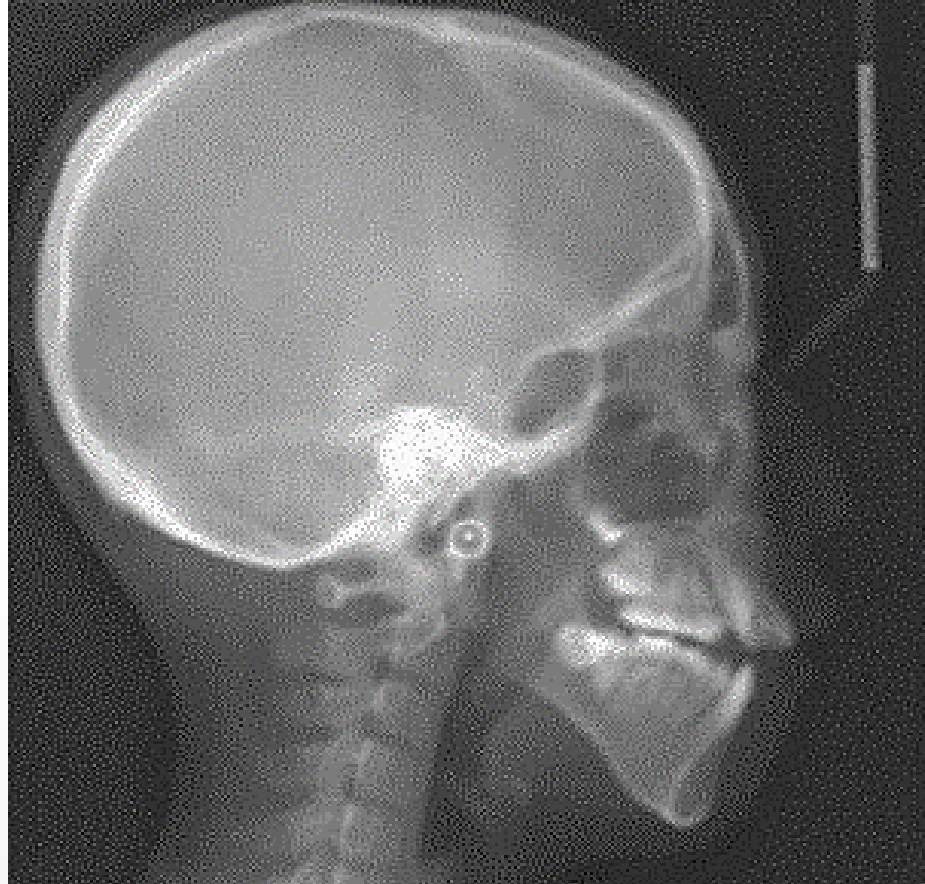Sample Case #6

Question 1



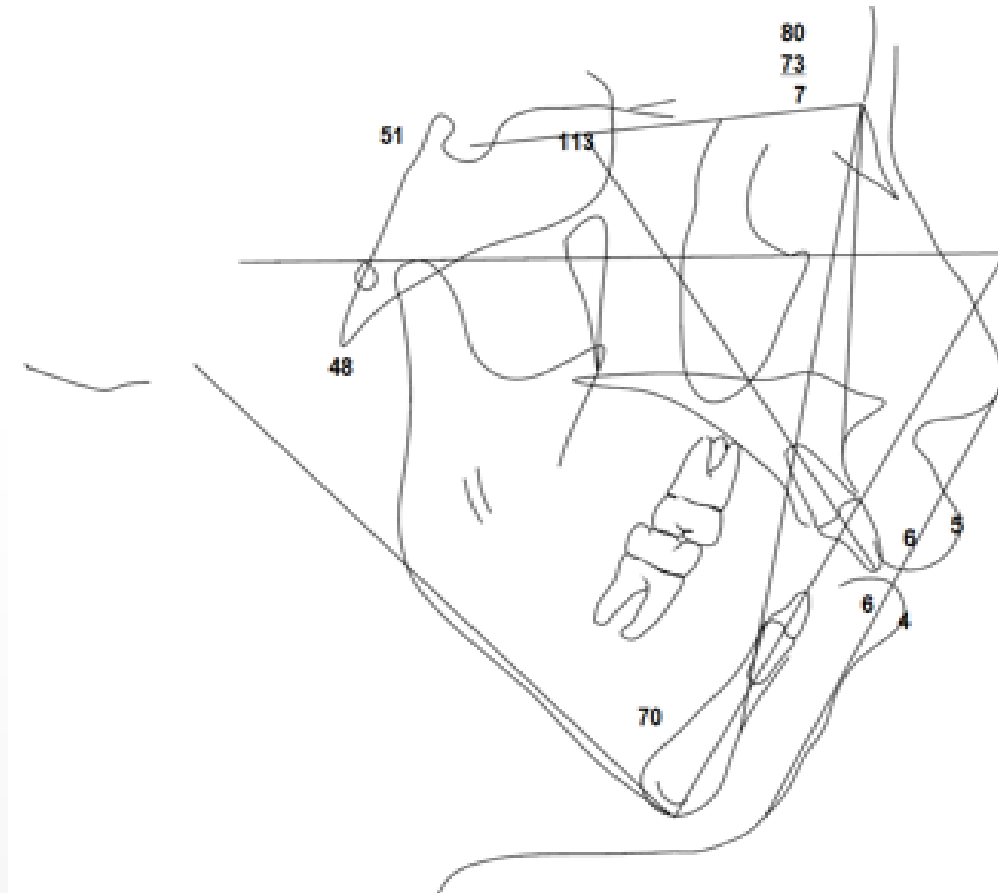
Sample Case #6

Question 1



Sample Case #6

Question 1



Sample Case #6

Question 1

A proficient response may include:

1. Steep mandibular plane
2. Increased gonial angle
3. Increased lower anterior facial height
4. Short ramus height
5. Decreased posterior facial height to anterior facial height ratio
6. Decreased palatal plane to SN angle
7. Constricted maxilla

Sample Case #6

Question 2

Classification

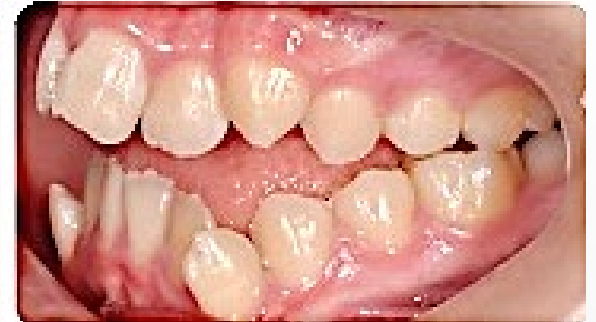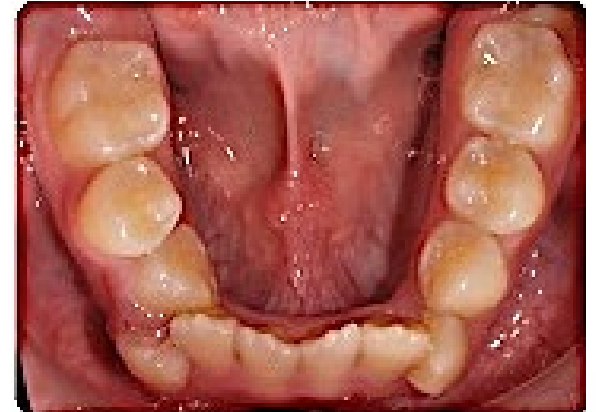
Domain 1: Data Gathering and Diagnosis

Prompt

List the dental components of this patient's open bite. Please list in numbered format below.

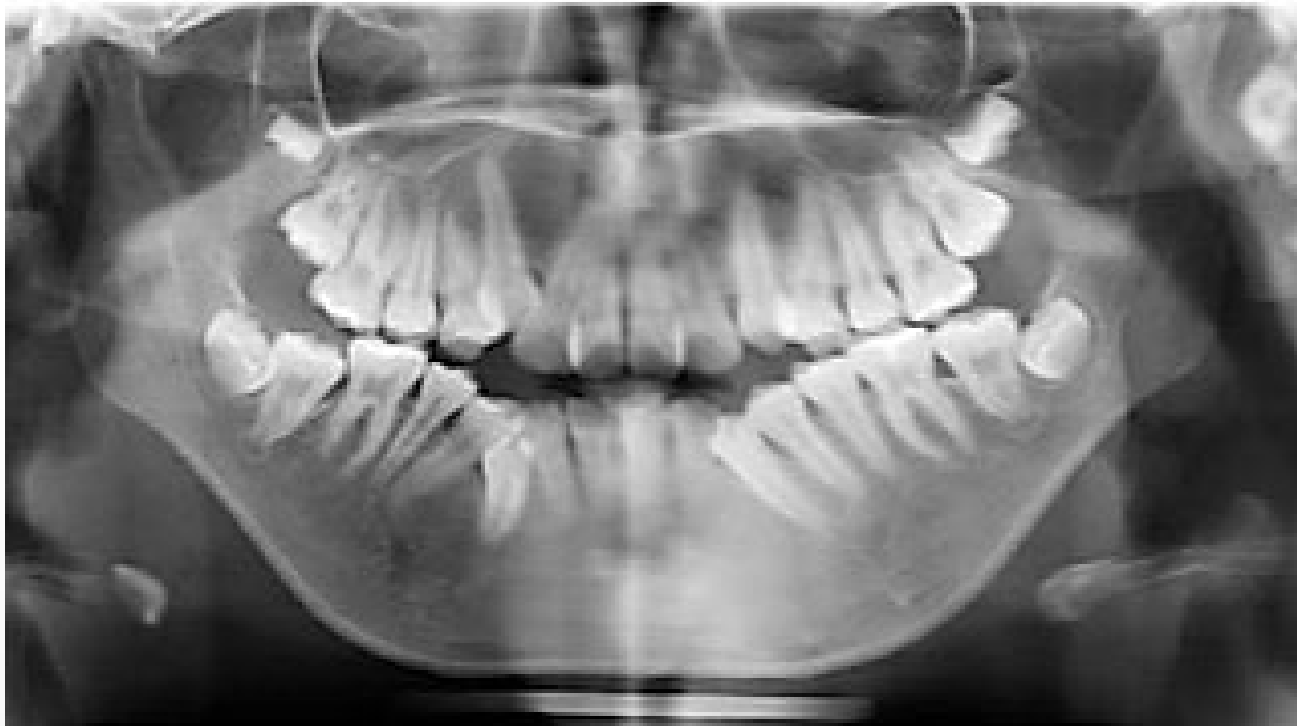Sample Case #6

Question 2



Sample Case #6

Question 2



Sample Case #6

Question 2



Sample Case #6

Question 2

A possible proficient response may include:

1. Constricted maxillary arch
2. Overeruption of maxillary molars
3. Proclination of maxillary incisors
4. Infra-erupted maxillary incisors
5. Overeruption of mandibular molars
6. Reverse curve of Spee in the mandibular arch (Infra-eruption of the mandibular incisors)
7. Increased curve of Spee in the maxillary arch
8. Increased curve of Wilson in the mandibular arch

Sample Case #6

Question 3

Classification

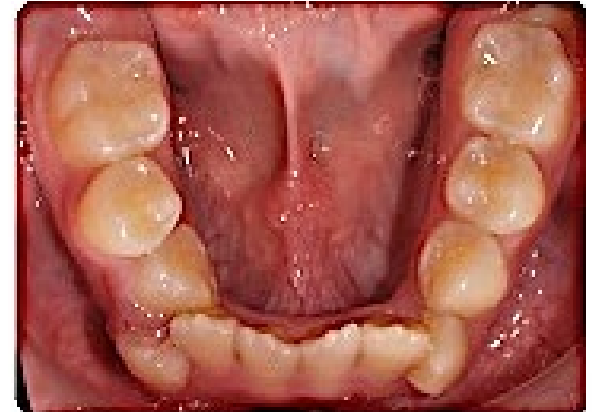
Domain 1: Data Gathering and Diagnosis

Prompt

Based on the intraoral photographs and cephalogram, what are the possible etiologies for this malocclusion? Please list in numbered format below.

Sample Case #6

Question 3



Sample Case #6

Question 3



Sample Case #6

Question 3

A proficient response may include:

1. Genetic component
2. Abnormal tongue size/posture
3. Abnormal tongue function
4. Inadequate airway/obligatory mouth breather
5. Myopathy or muscle weakness

Sample Question #6

Question 4

Classification

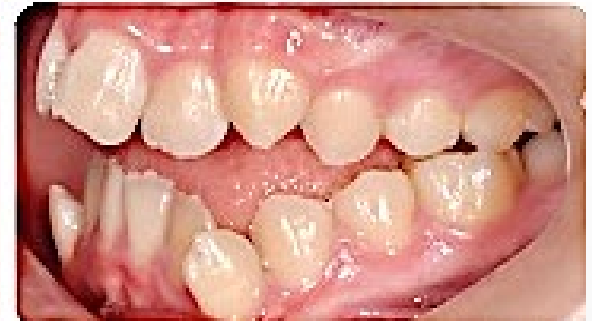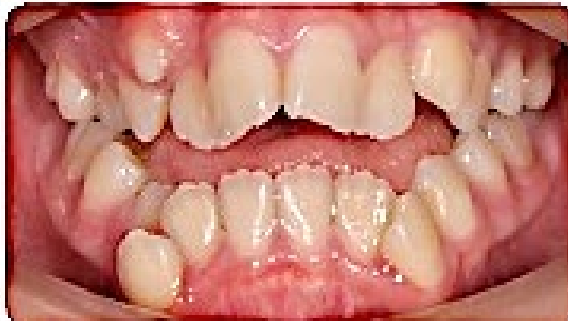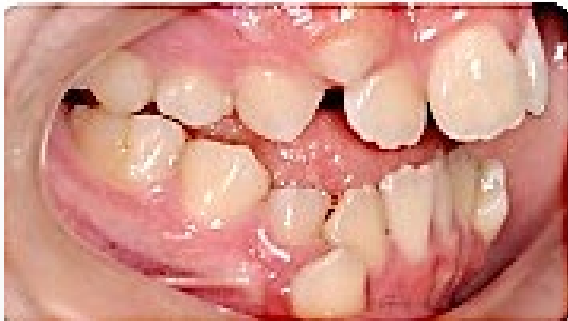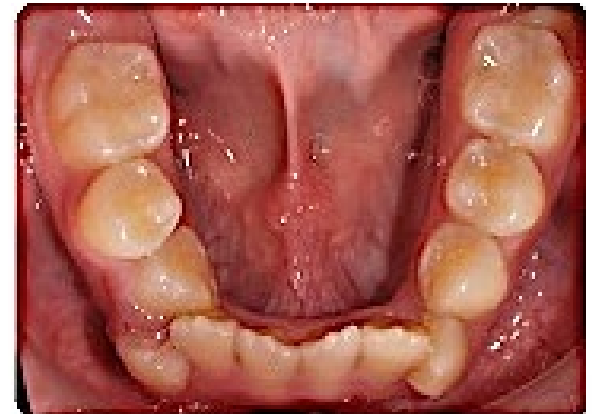
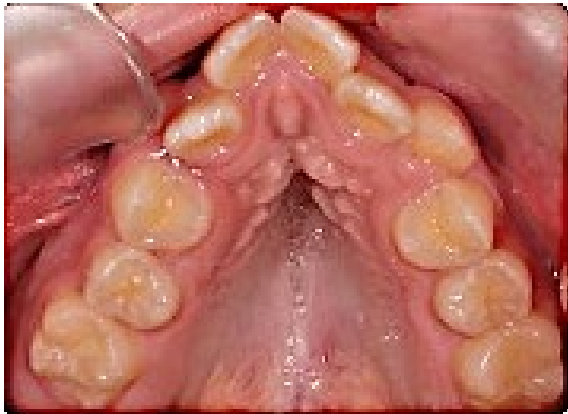Domain 1: Data Gathering and Diagnosis

Prompt

Based on the images you have seen so far, what other diagnostic tests or assessments would you undertake or request prior to initiating treatment on this patient? Please list in numbered format below.

Sample Case #6

Question 4



Sample Case #6

Question 4



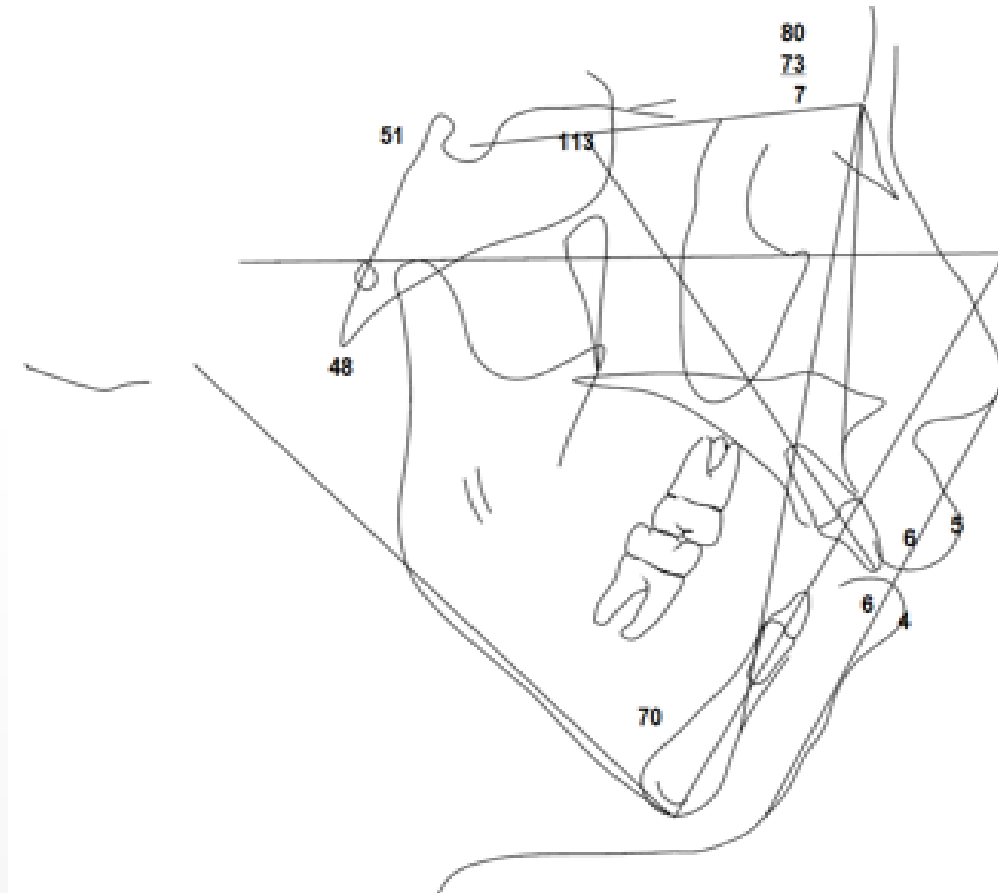
Sample Case #6

Question 4



Sample Case #6

Question 4



Sample Case #6

Question 4

A proficient response may include:

1. CBCT
2. Airway assessment (polysomnography)
3. Evaluation of tongue posture (Myofunctional evaluation)
4. Evaluation of tongue function (Myofunctional evaluation)
5. Electromyographic evaluation
6. Serial cephalograms to determine whether progressive or static problem
7. TEC99 scan

Sample Case #6

Question 5

Classification

Domain 2: Treatment Objectives and Planning

Prompt

Assuming orthognathic surgical correction, describe the ideal skeletal treatment objectives for this patient. Please list in numbered format below.

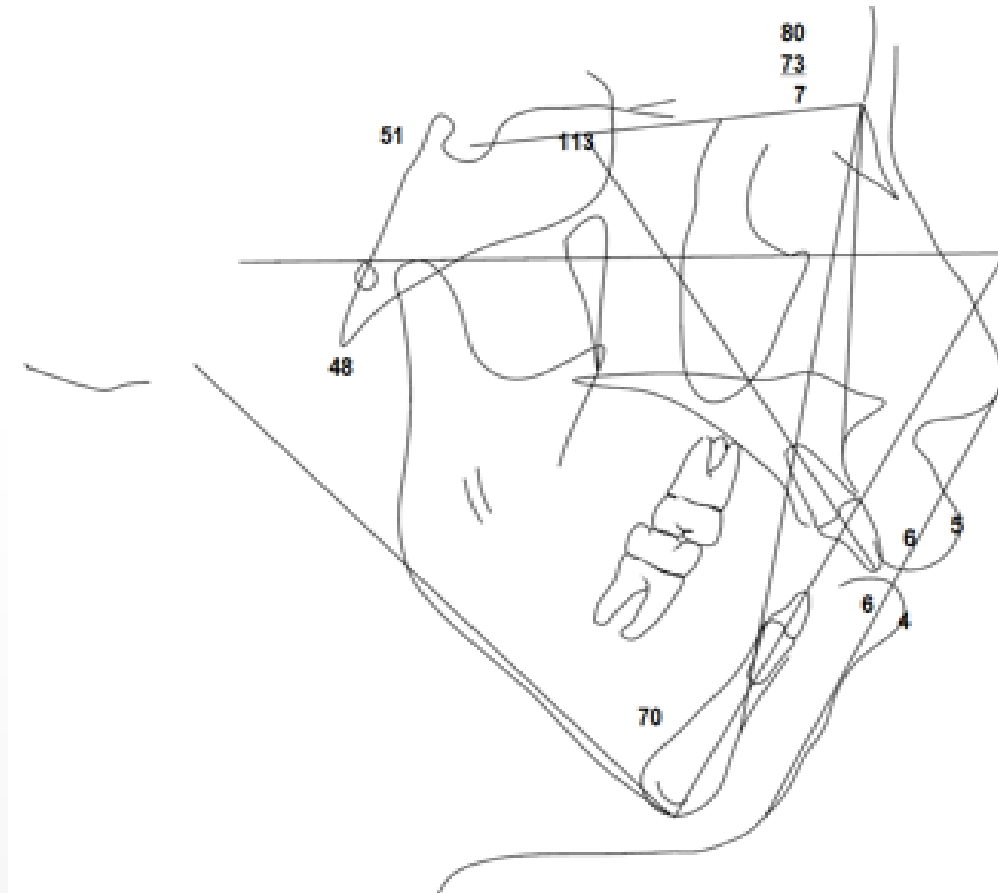
Sample Case #6

Question 5



Sample Case #6

Question 5



Sample Case #6

Question 5

A proficient response may include:

1. Maxillary advancement
2. Maxillary expansion
3. Posterior maxillary impaction
4. Reduction of lower anterior facial height
5. Reduction of SN mandibular plane angle
6. Advance the mandible (improvement of chin projection)

Sample Case #6

Question 6

Classification

Domain 2: Treatment Objectives and Planning

Prompt

Describe the ideal treatment plan for this patient. Please list in numbered format below.

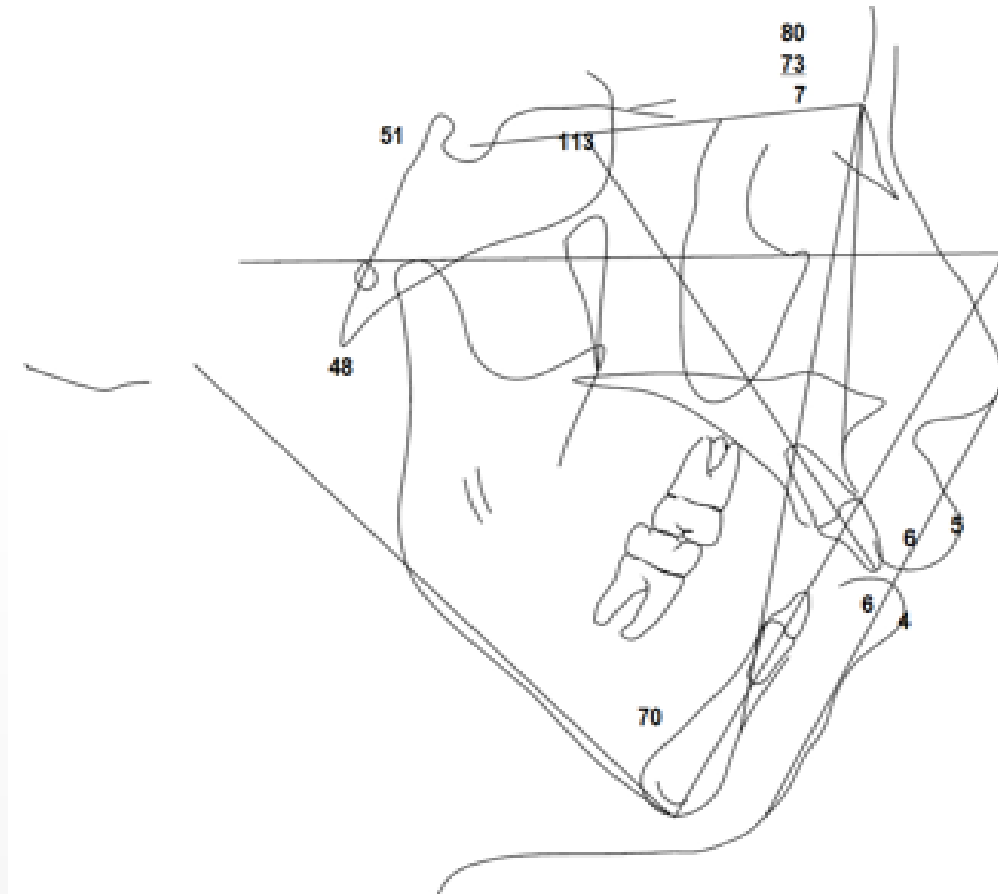
Sample Case #6

Question 6



Sample Case #6

Question 6



Sample Case #6

Question 6

A proficient response may include:

1. Maxillary orthopedic expansion, or surgically assisted maxillary expansion (SARME), or segmental Le Fort I surgery
2. Extraction of two maxillary premolars
3. Extraction of all third molars
4. Maxillary LeFort I surgery with posterior impaction
5. Mandibular forward rotation and bilateral sagittal split ramus osteotomy for advancement
6. Vertical reduction/AP augmentation genioplasty

Sample Case #6

Question 7

Classification

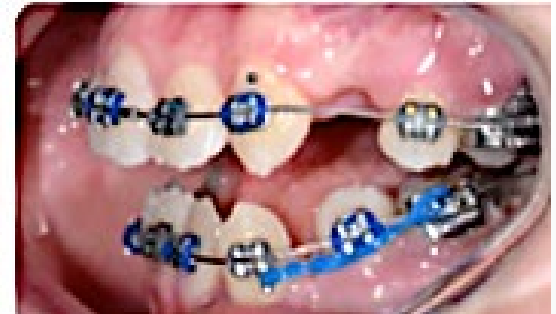
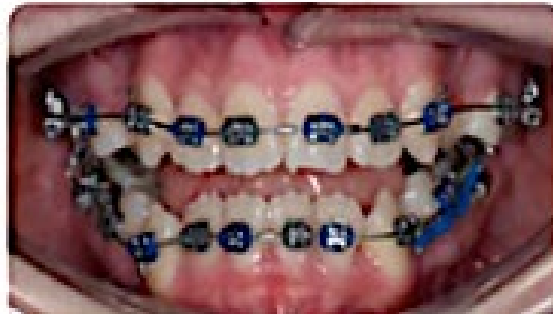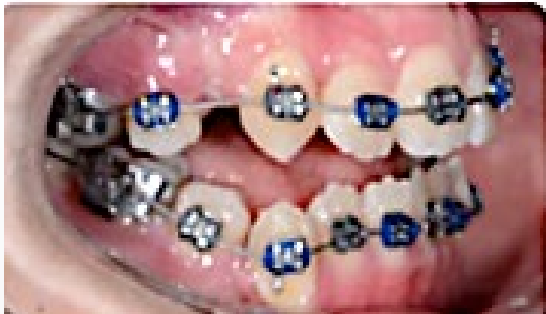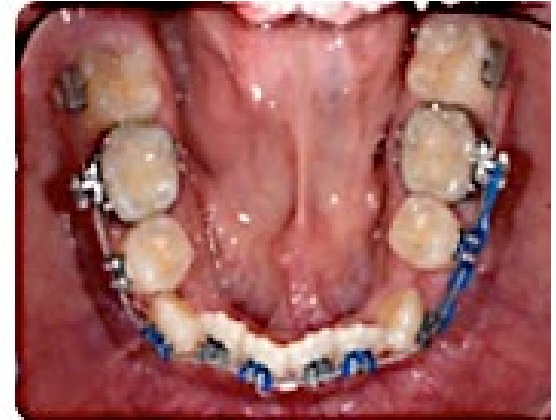
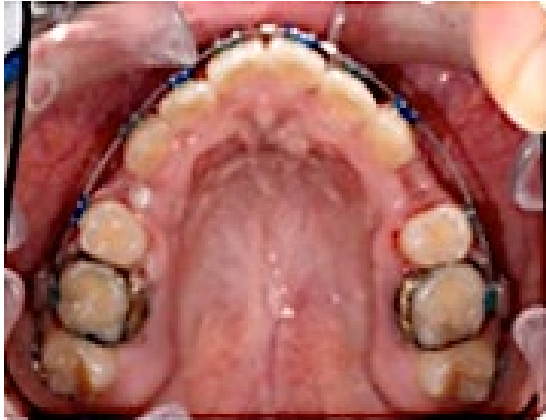Domain 3: Treatment Implementation and Management

Prompt

The patient has declined orthognathic surgery after treatment has been implemented. What are the next steps to attempt to correct the patient's open bite? Please list in numbered format below.

Sample Case #6

Question 7



Sample Case #6

Question 7

A proficient response may include:

1. Trans-palatal arch
2. Mandibular lingual arch
3. Intrusion of mandibular molars using TADs
4. Intrusion of maxillary molars using TADs or zygomatic plates

Sample Case #7



The highest commitment to excellence.

Sample Case #7

Question 1

Opening Scenario:

- Chief Complaint: “My front teeth don’t fit right and I don’t like my smile”.

Sample Case #7

Question 1

Classification

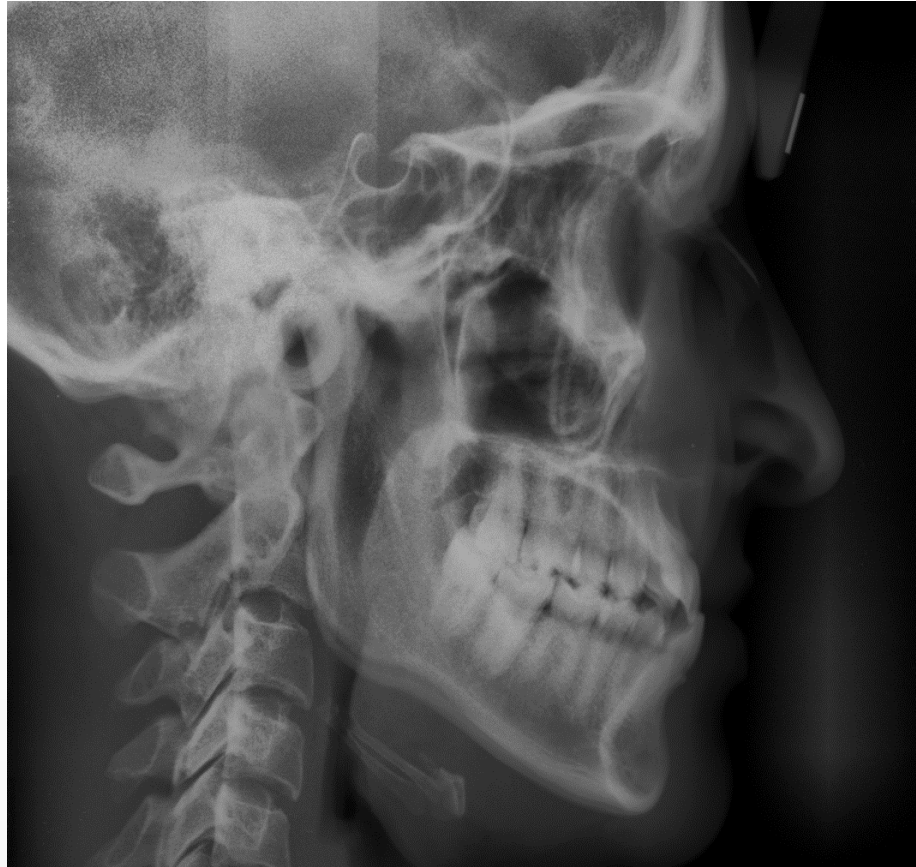Domain: Data Gathering and Diagnosis

Prompt

What cephalometric measurements may be used for the diagnosis of vertical skeletal pattern of this patient? Please list in numbered format below.

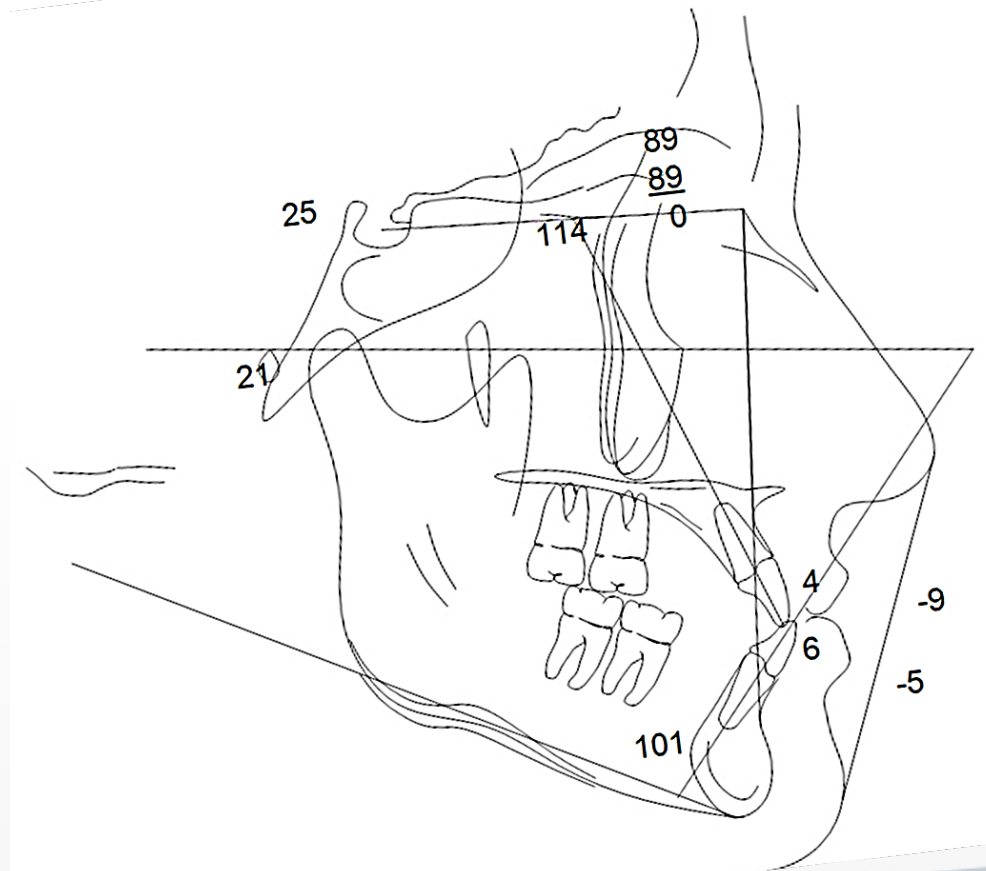
Sample Case #7

Question 1



Sample Case #7

Question 1



Sample Case #7

Question 1

Fully Proficient Model Response

- The candidate must include 5 of the following:
 1. FMA
 2. GoGn-SN (OR constructed GoMe-SN)
 3. N-Me (mm)
 4. S-Go (mm)
 5. S-Go/N-Me (%)
 6. ANS-Me
 7. Gonial angle
 8. Y-axis

Borderline Proficient Model Response

- The candidate must include 4 of the above

Not Proficient Model Response

- The candidate includes 3 or fewer of the above

Sample Case #7

Question 2

Classification

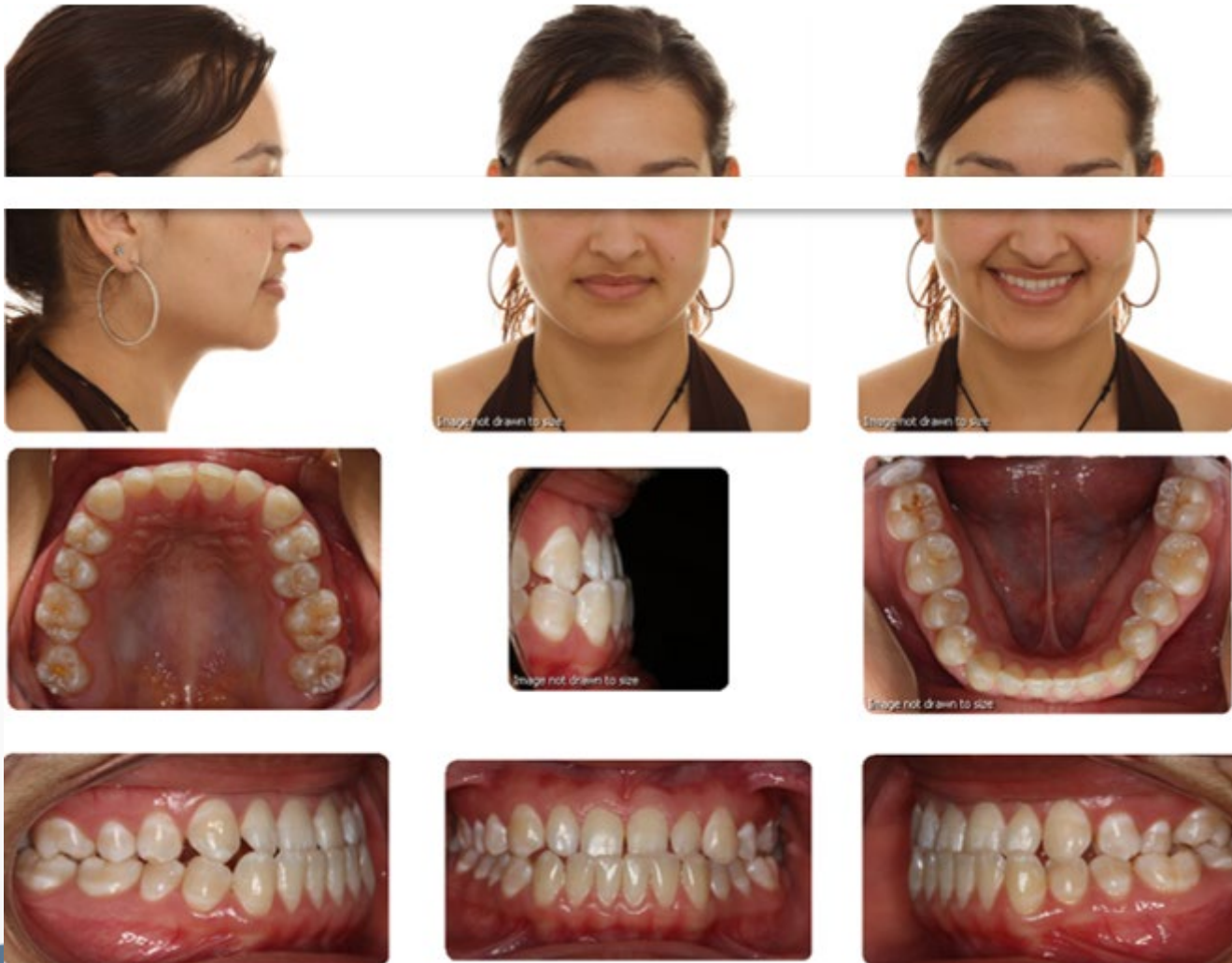
Domain: Data Gathering and Diagnosis

Prompt

Describe your interpretation of the initial cephalometric tracing.

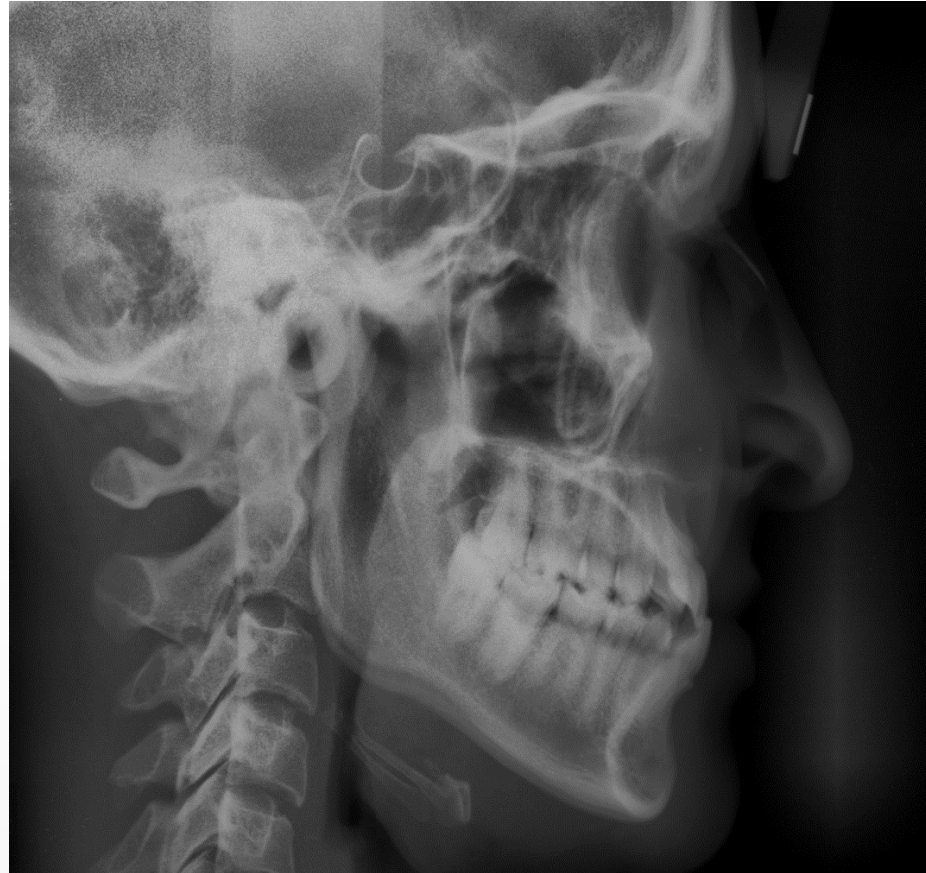Sample Case #7

Question 2



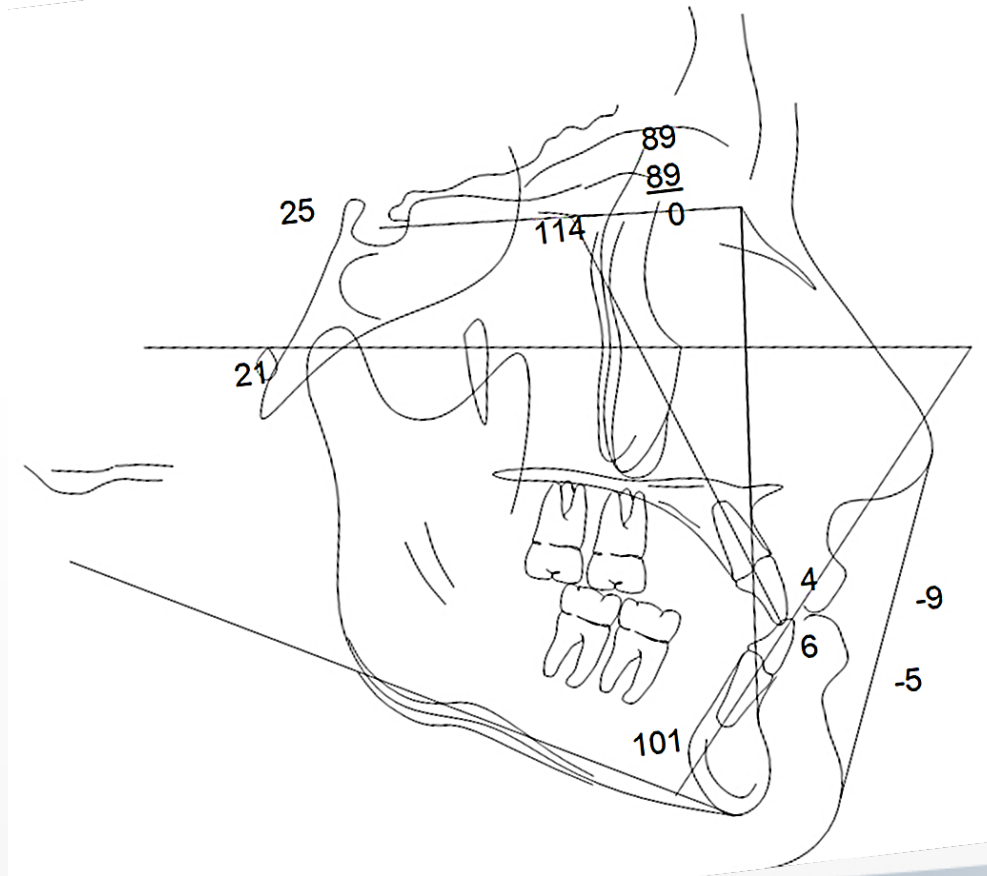
Sample Case #7

Question 2



Sample Case #7

Question 2



Sample Case #7

Question 2

Fully Proficient Model Response

- The candidate must include 6 or more of the following:
 1. Canted (Flat) anterior cranial base (SN)
 2. Skeletal Class III (ANB: 0)
 3. Retrognathic maxilla (or mid-face deficiency)
 4. Prognathic mandible
 5. Proclined maxillary incisors
 6. Proclined mandibular incisors
 7. Retruded upper lip to E-line
 8. Decreased FMA

Borderline Proficient Model Response

- The candidate must include 5 of the above.

Not Proficient Model Response

- The candidate includes 4 or fewer of the above.

Sample Case #7

Question 3

Classification

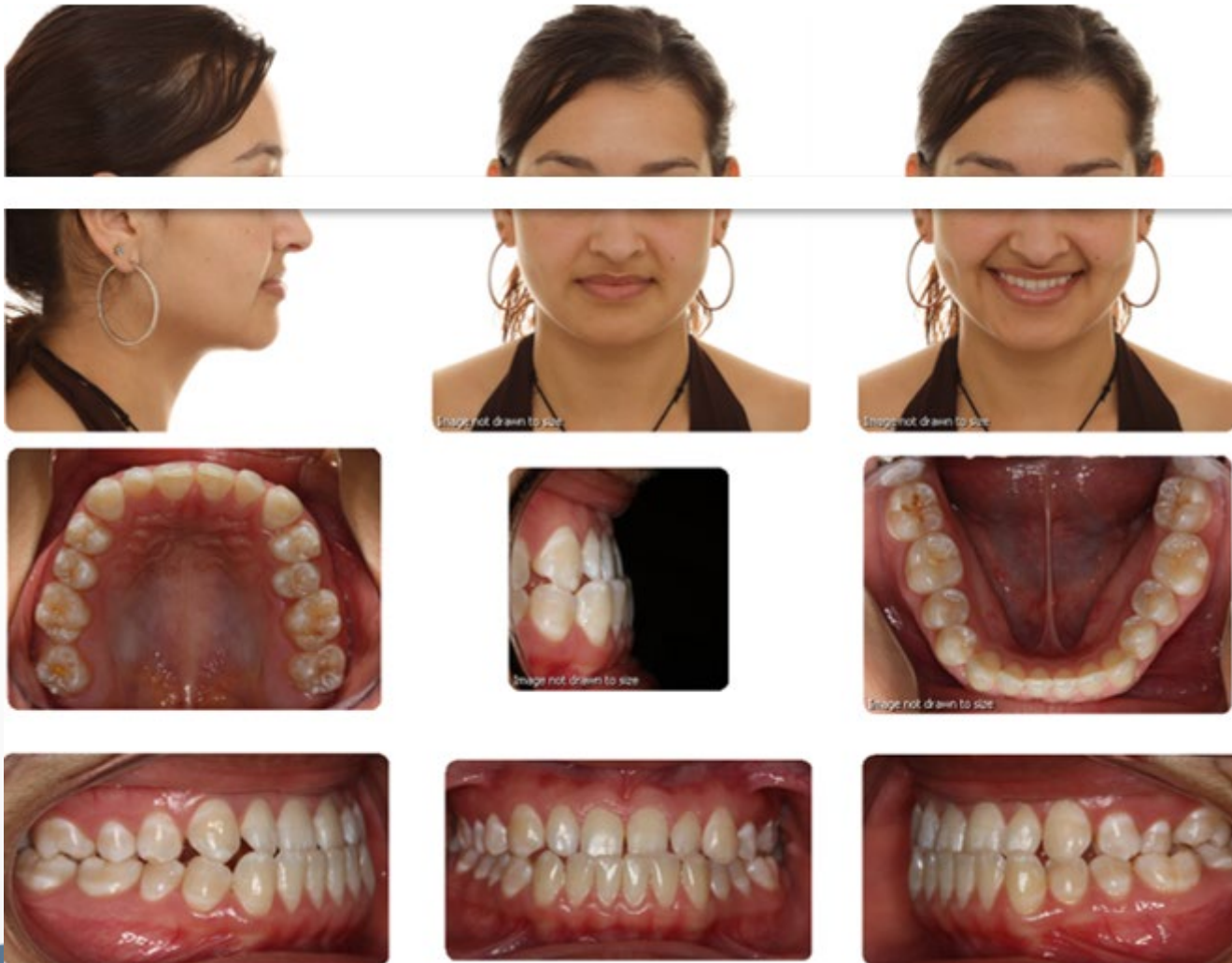
Domain: Treatment Objectives and Planning

Prompt

Assuming this patient has no facial concerns and denies orthognathic surgery, what are your dental and skeletal treatment objectives? Please list in numbered format below.

Sample Case #7

Question 3



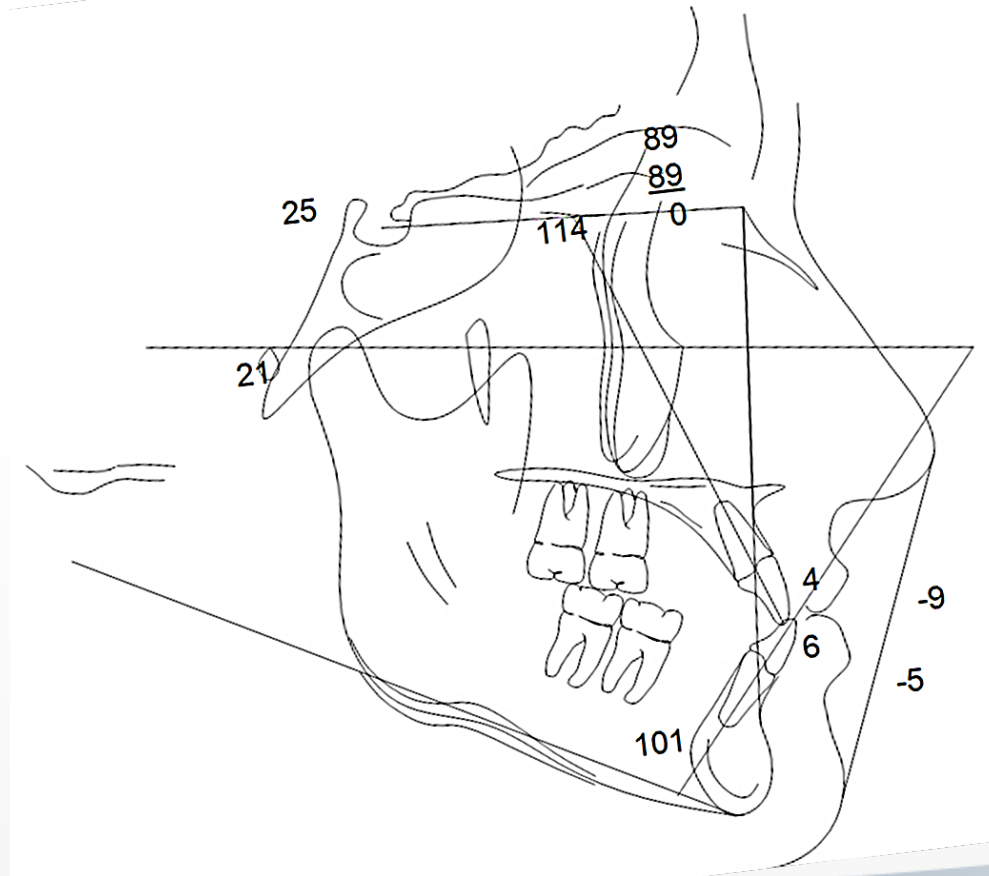
Sample Case #7

Question 3



Sample Case #7

Question 3



Sample Case #7

Question 3

Fully Proficient Model Response

- The candidate must include 7 or more of the following:
 1. Obtain Class I canine and molar relationship
 2. Maintain the maxillary incisor A-P position.
 3. Lingual crown torque and retract the mandibular incisors
 4. Distalize the mandibular posterior teeth
 5. Correct the anterior cross-bite
 6. Establish proper overbite and overjet
 7. Correct the posterior cross-bites (maxillary right second molar and maxillary left second premolar)
 8. Maintain mandibular inter-canine width
 9. Increase tooth display on smiling
 10. Make provisions to address the Bolton tooth size discrepancy

Sample Case #7

Question 3

Borderline Proficient Model Response

- The candidate must include 4 of the above.

Not Proficient Model Response

- The candidate includes 3 or fewer of the above.

Sample Case #7

Question 4

Classification

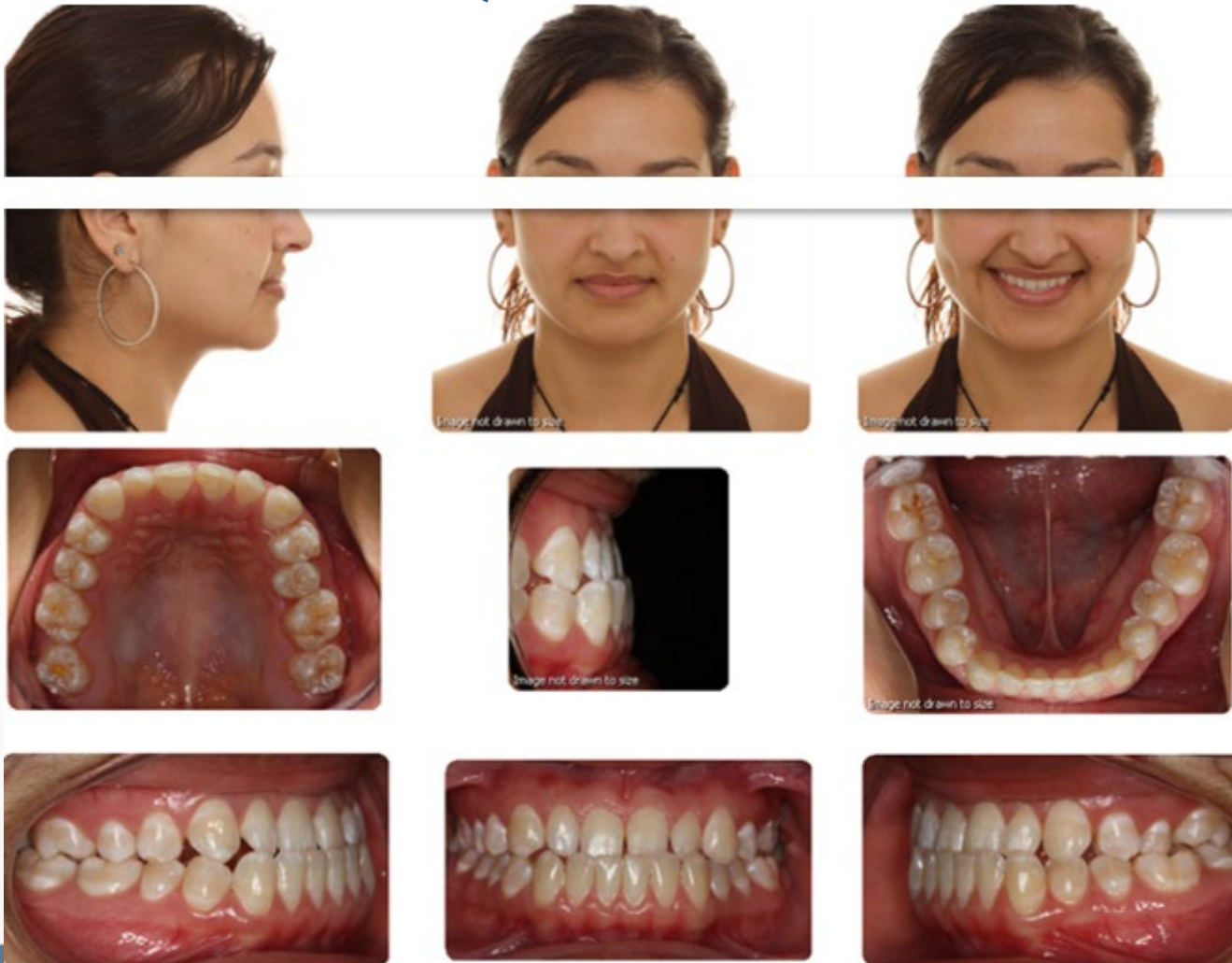Domain: Treatment Objectives and Planning

Prompt

Using the post-treatment records and superimposition, identify possible treatment mechanics that could achieve the observed results. Please list in numbered format below.

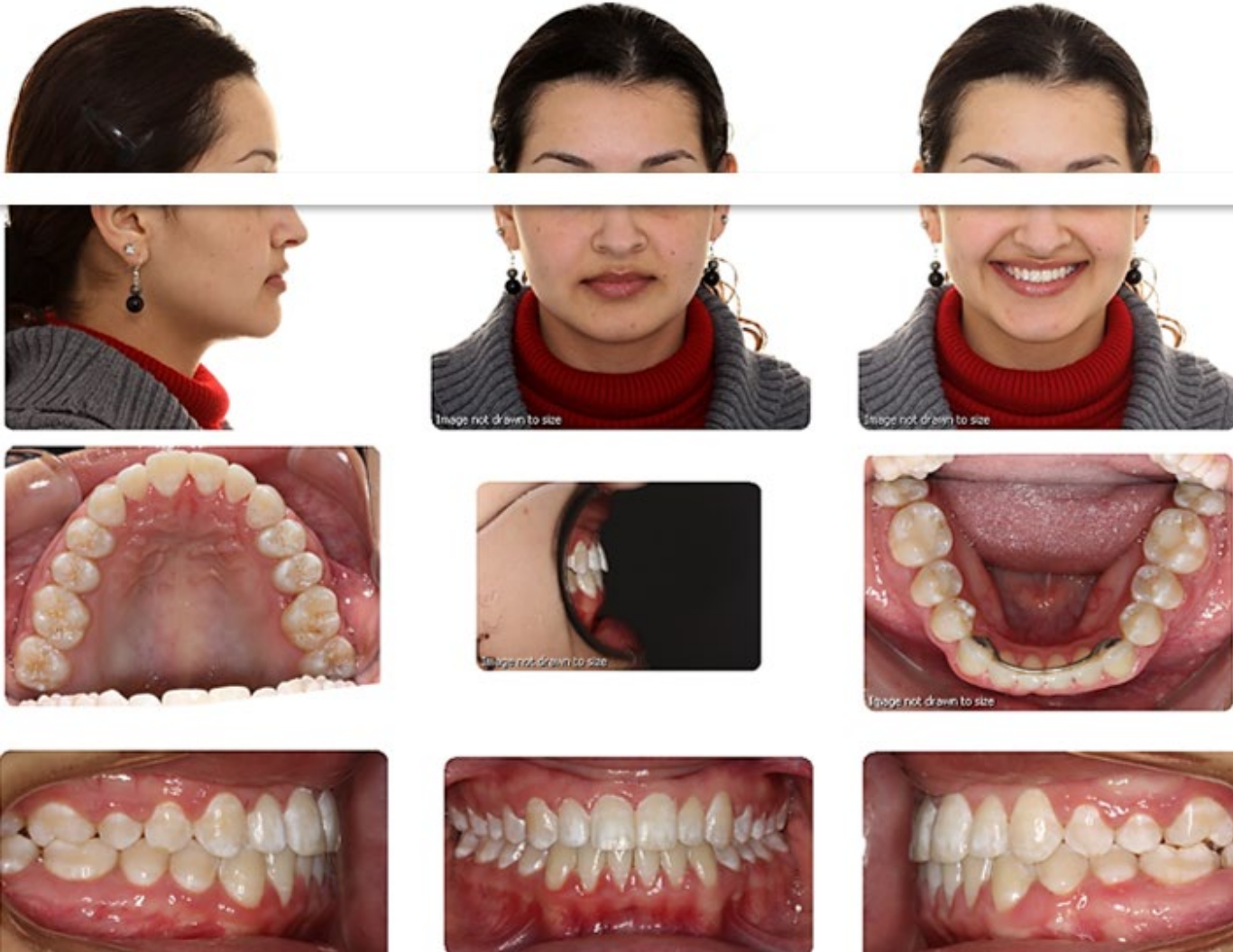Sample Case #7

Question 4



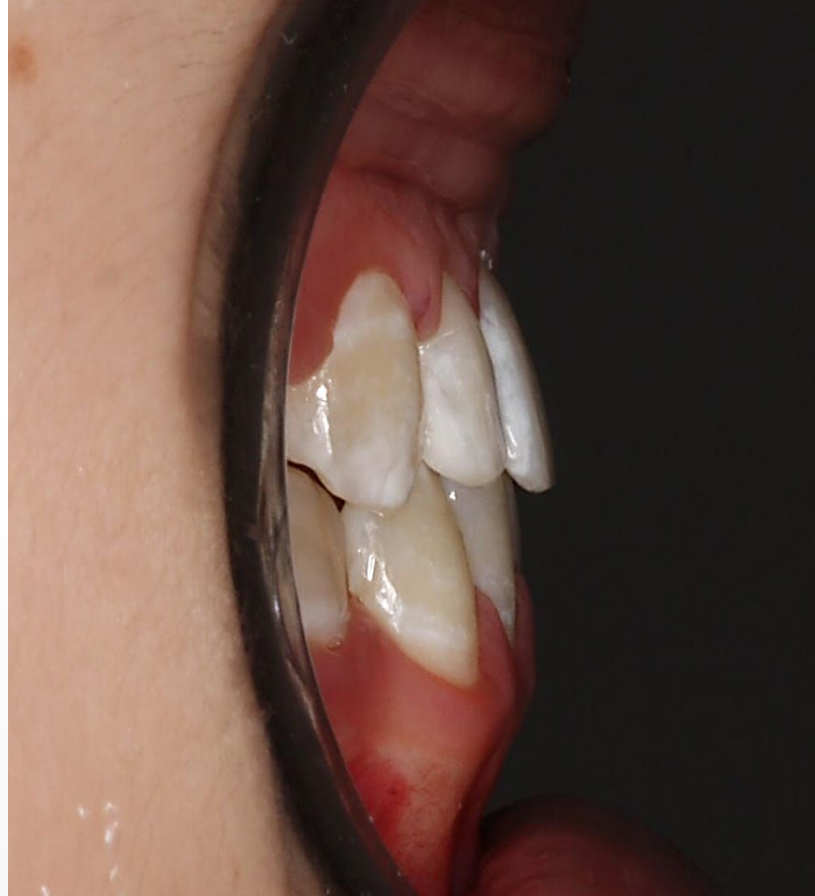Sample Case #7

Question 4



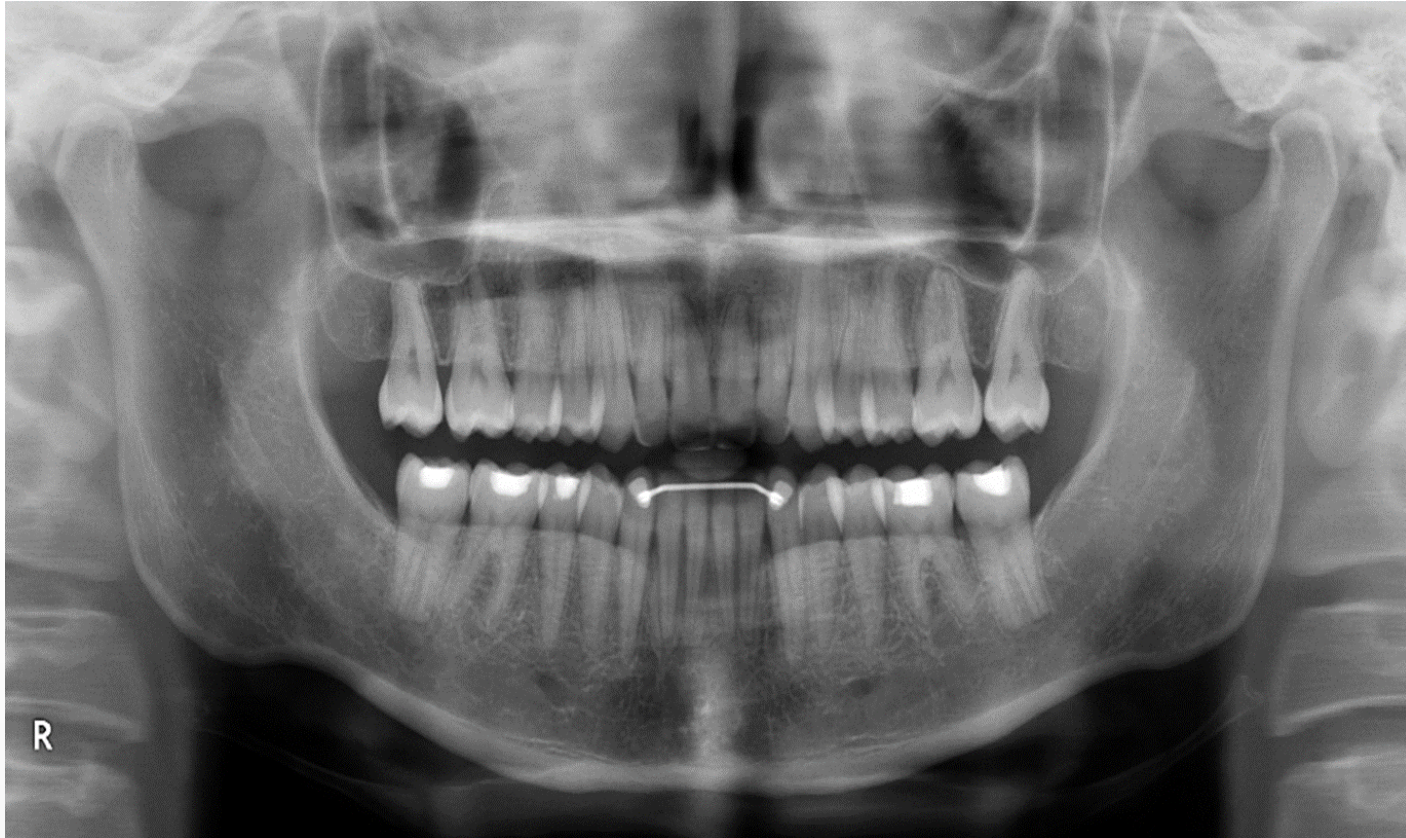Sample Case #7

Question 4



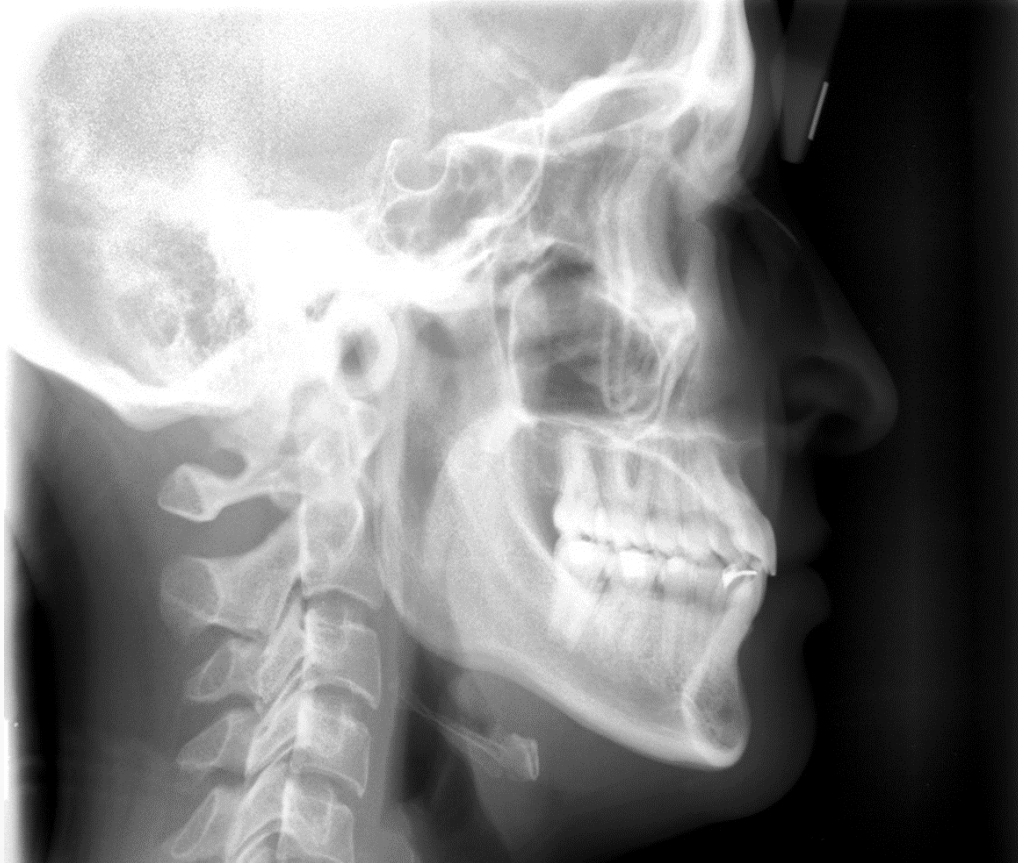Sample Case #7

Question 4



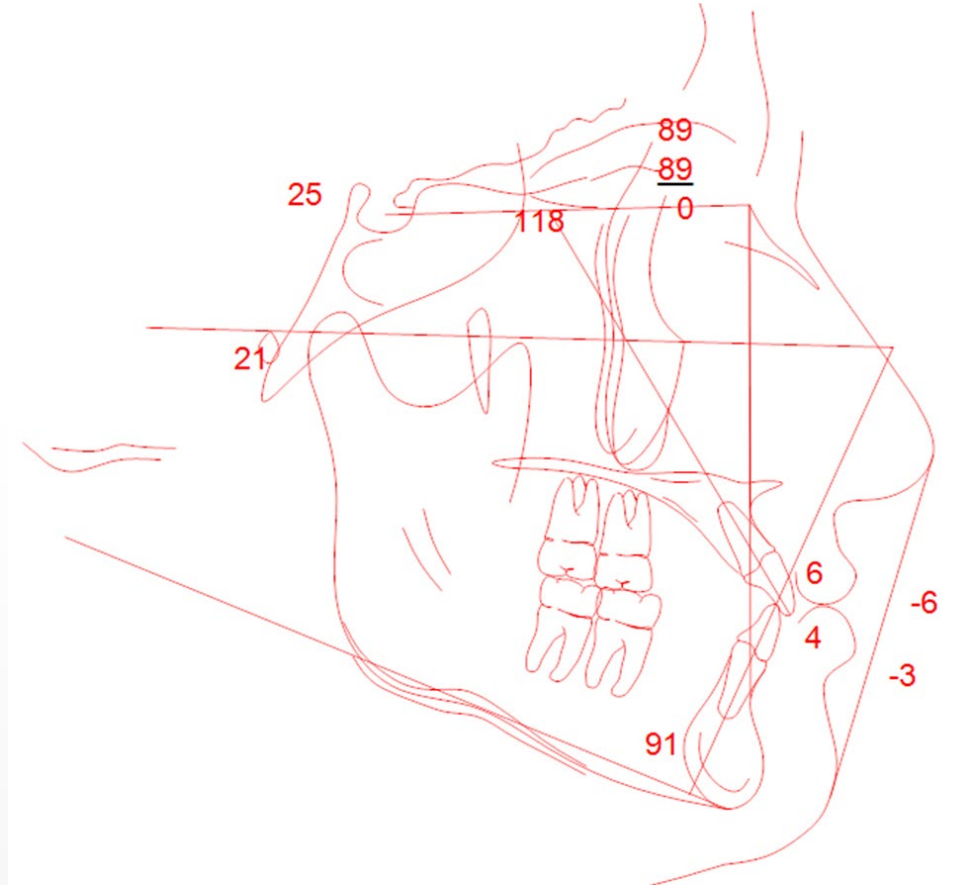
Sample Case #7

Question 4



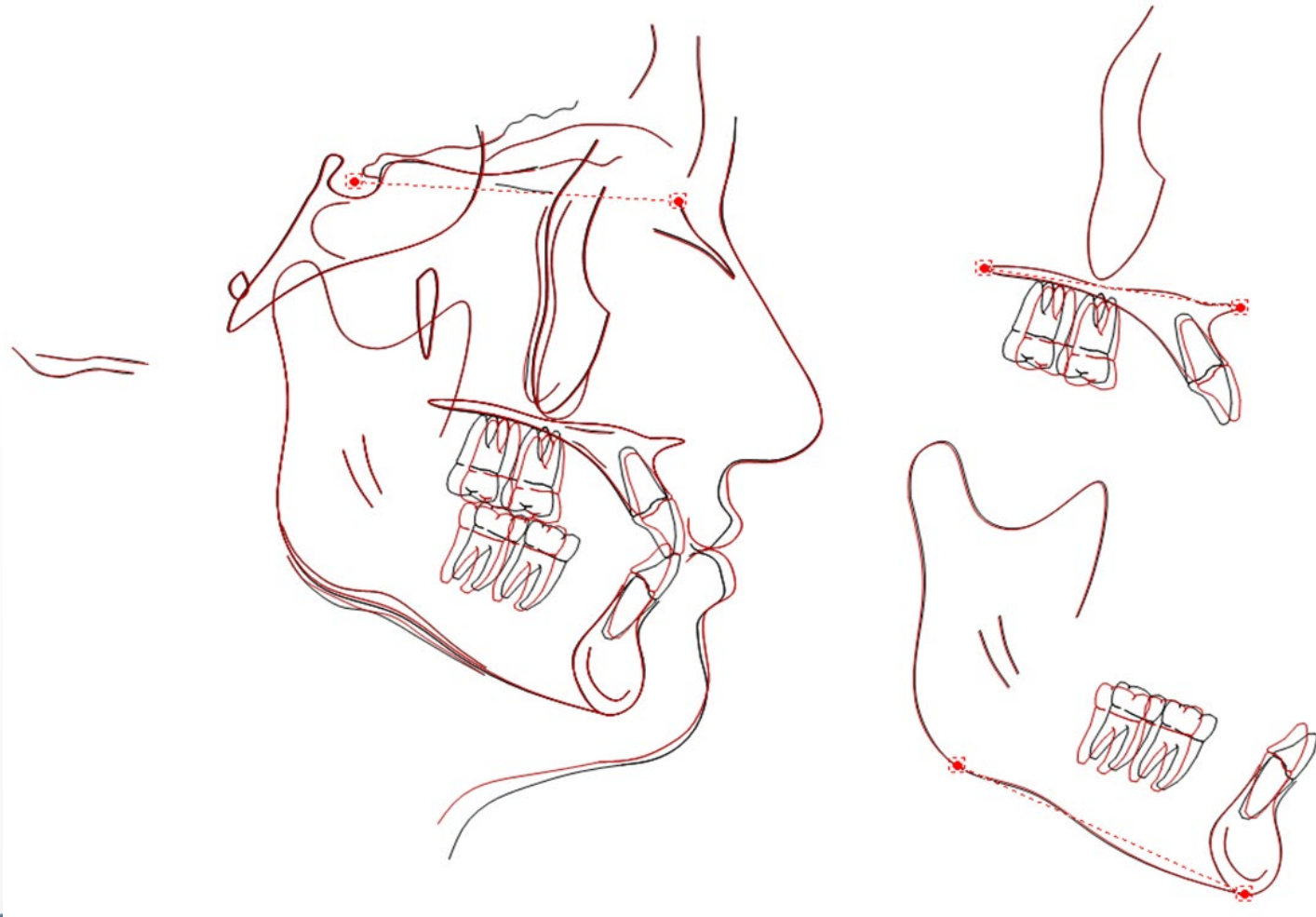
Sample Case #7

Question 4



Sample Case #7

Question 4



Sample Case #7

Question 4

Fully Proficient Model Response

- Candidate must include all of the following:
 1. Distalization of the mandibular dentition using intra-arch mechanics and TADs as anchorage
 2. Mesialization of the maxillary dentition
 3. IPR on mandibular anterior teeth
 4. Reduced use of Class III elastics
 5. Utilization of short class III elastics

Borderline Proficient Model Response

- Candidate must include the following:
 - Distalization of the mandibular dentition using intra-arch
 - And include 2 or more of the above.

Not Proficient Model Response

- Candidate fails to include:
 - Distalization of the mandibular dentition using intra-arch
 - Or includes distalization of the mandibular dentition using intra-arch, but includes one or fewer of the above.

Sample Case #7

Question 5

Classification

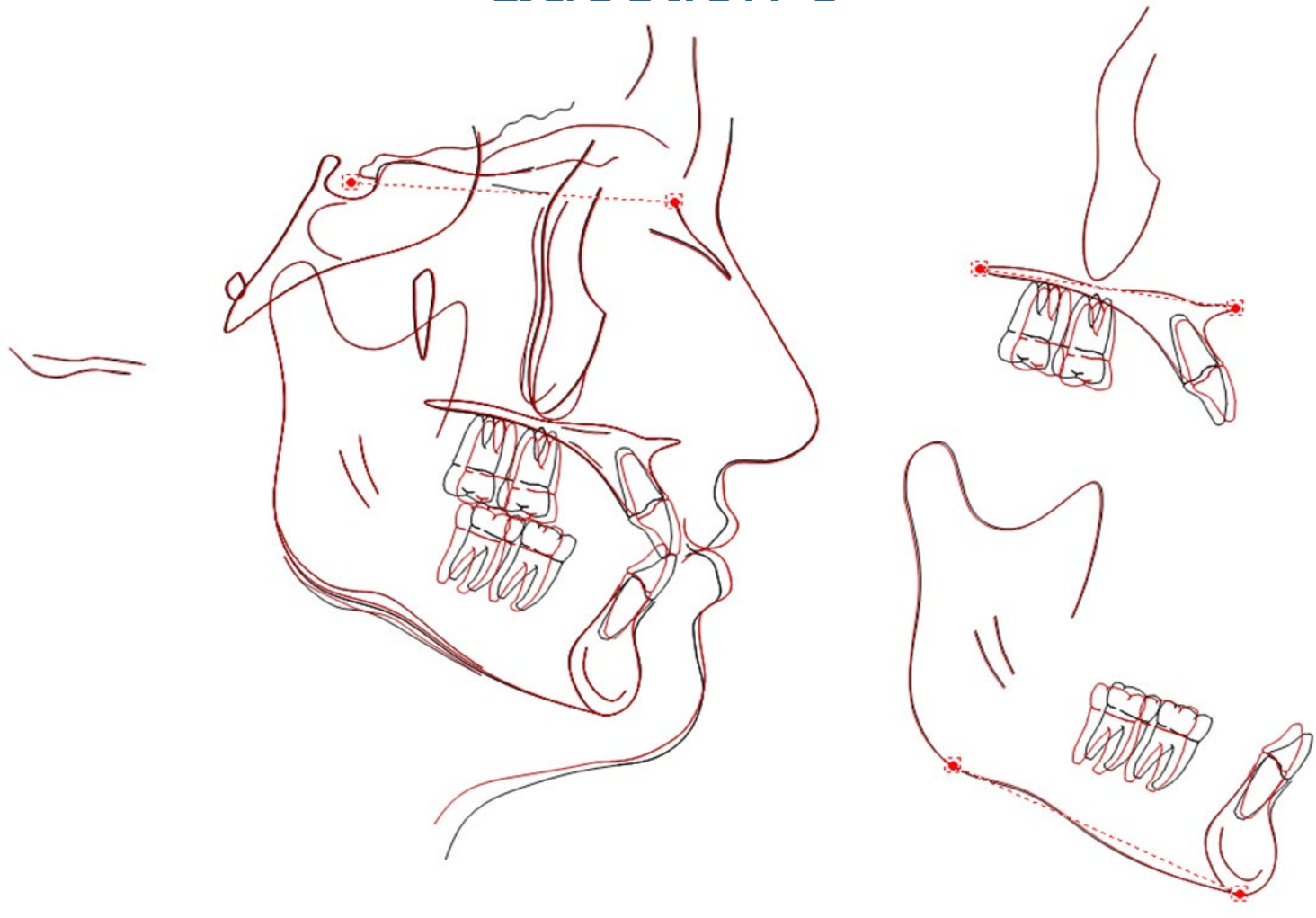
Domain: Critical analysis and outcomes assessment

Prompt

Please interpret the superimpositions regarding the dental and skeletal changes from treatment. Please list in numbered format below.

Sample Case #7

Question 5



Sample Case #7

Question 5

Fully Proficient Model Response

- The candidate must include 6 or more of the following:
 1. Increased maxillary incisor proclination
 2. Increased mandibular incisor retroclination
 3. Slight extrusion of the maxillary molars
 4. Maxillary molars moved mesially
 5. Mandibular molars moved distally
 6. No skeletal changes noted from treatment
 7. Slight advancement of upper and lower lips/improved lip projection

Sample Case #7

Question 5

Borderline Proficient Model Response

- The candidate must include 5 of the above

Not Proficient Model Response

- The candidate includes 4 or fewer of the above