

Scenario-based Clinical Exam

Cast Radiograph Evaluation (CRE)/
Case Management Form (CMF)/
Superimposition
Preparation Materials &
Sample Cases



The highest commitment to excellence.

Disclaimer

- The following sample questions and answers were composed and vetted by a panel of experts in orthodontics and are intended to provide an example of the types of cases and questions that make up the actual scenario-based clinical examination.
- After the examination, trained examiners, who are all board certified orthodontists, will score the typed responses using rubrics as guides to their decision making.
- Rubrics help to create consistency in the decisions the examiners make while grading an examinees typed responses. The rubrics are not absolute, as there may be other acceptable answers that are not listed.

Disclaimer Continued

- The ABO has developed multiple versions of the case-based scenario examination to be used during a test administration cycle. Although the set of cases and questions used on the different versions will not all be the same, all versions follow the same content framework as defined by the practice analysis study.
- Scores will be computed using equating procedures to ensure that all versions are of the same difficulty.
- Review of these sample cases does not guarantee that a candidate will pass the examination.
- Examinee responses to exam questions will be typed out and should be in numbered list format (i.e., short and concise, no essay responses).

Cast-Radiograph Evaluation (CRE)



The highest commitment to excellence.

For the Cast-Radiograph Evaluation (CRE), examinees will be shown a series of records which may include: images of models, still shots of the models using the Ortho Share 3D CRE online software, and/or panoramic radiographs (as needed). Examinees will be asked to answer questions based on the information provided.

- Examinees will need to be familiar with grading digital models using the online software.
- Examinees will NOT be given the CRE Parameters reference guide (for use with the Ortho Share 3D – Online software) during the exam.
- Examinees need to be prepared to answer some **specific** critical thinking questions related to the different CRE parameters.
- Examinees will need to recognize correct landmark positions on study models using online software.

Examinees will need to be familiar with the following parameters as they will NOT be provided during the examination.

Reference - ABO Cast/Radiograph Evaluation Parameters For use with Ortho Share 3D – Online	
See ABO Model Analysis/Landmark Locations for entire discussion	
<p><u>ALIGNMENT/ROTATIONS</u></p> <p>0 – 0.5 mm = satisfactory (0) 0.6 – 1 mm = 1 for each tooth > 1 mm = 2 for each tooth</p>	<p><u>OCCLUSAL CONTACTS</u></p> <p>Not scored in Ortho Share 3D</p>
<p><u>MARGINAL RIDGES</u></p> <p>0 – 0.5 mm = satisfactory (0) 0.6 – 1 mm = 1 (for each interproximal contact > 1 mm = 2 between posterior teeth)</p> <p>** Do not include the canine-premolar contact. Do not include the distal of lower 1st premolar.</p>	<p><u>OCCLUSAL RELATIONSHIP</u></p> <p>=/< 1 mm = satisfactory (0) 1.1 - 2 mm = 1 (for each maxillary tooth from the > 2 mm = 2 the canines to the 2nd molars)</p>
<p><u>BUCCOLINGUAL INCLINATION</u></p> <p>0 - 1 mm = satisfactory (0) 1.1 - 2 mm = 1 (for each posterior tooth) > 2 mm = 2</p> <p>** Do not score the mandibular 1st premolars nor the distal cusps of the second molars.</p>	<p><u>INTERPROXIMAL CONTACTS</u></p> <p>Not scored in Ortho Share 3D</p>
<p><u>OVERJET</u></p> <p>Anterior teeth must be contacting.</p> <p>0 – 0.5 mm = satisfactory (0) 0.6 – 1.5 mm = 1 (for each maxillary tooth) > 1.5 mm = 2</p>	<p><u>ROOT ANGULATION</u></p> <p>Parallel = 0 Not parallel = 1 Root contacting adjacent root = 2 (for each occurrence)</p> <p>Do not score the maxillary and mandibular canine relationships with adjacent tooth when using a final panoramic radiograph unless the radiograph was taken by a CBCT.</p>
<p><u>NOTE:</u> The sensitivity of the computer-generated measurements allows for greater precision, therefore, the parameters for alignment/rotations, marginal ridges, and overjet have been adjusted. Third molars are not scored unless they substitute for the second molars. No tooth is scored more than two points per individual parameter.</p>	

CRE Sample Case

Question 1

Classification

Domain 4: Critical Analysis and Outcomes Assessment

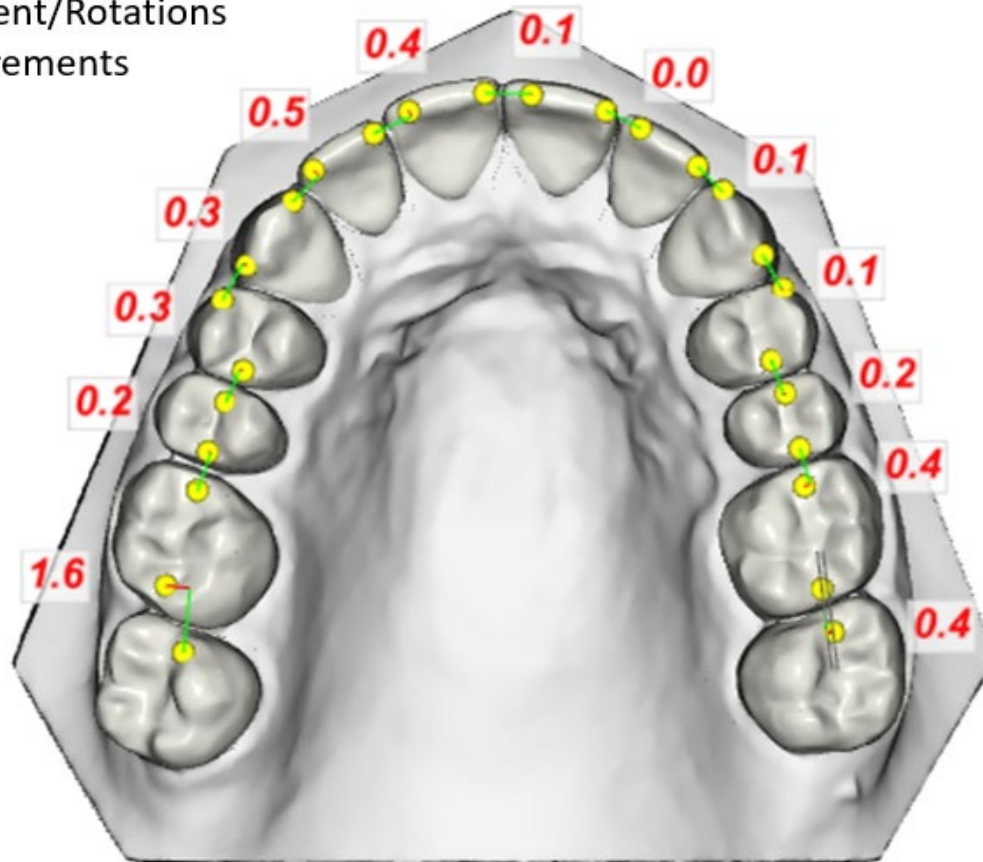
Prompt

What are the individual scores for the following CR-Eval parameters:
Alignment / Rotations, Marginal Ridges, and Buccolingual Inclination?

CRE Sample Case

Question 1

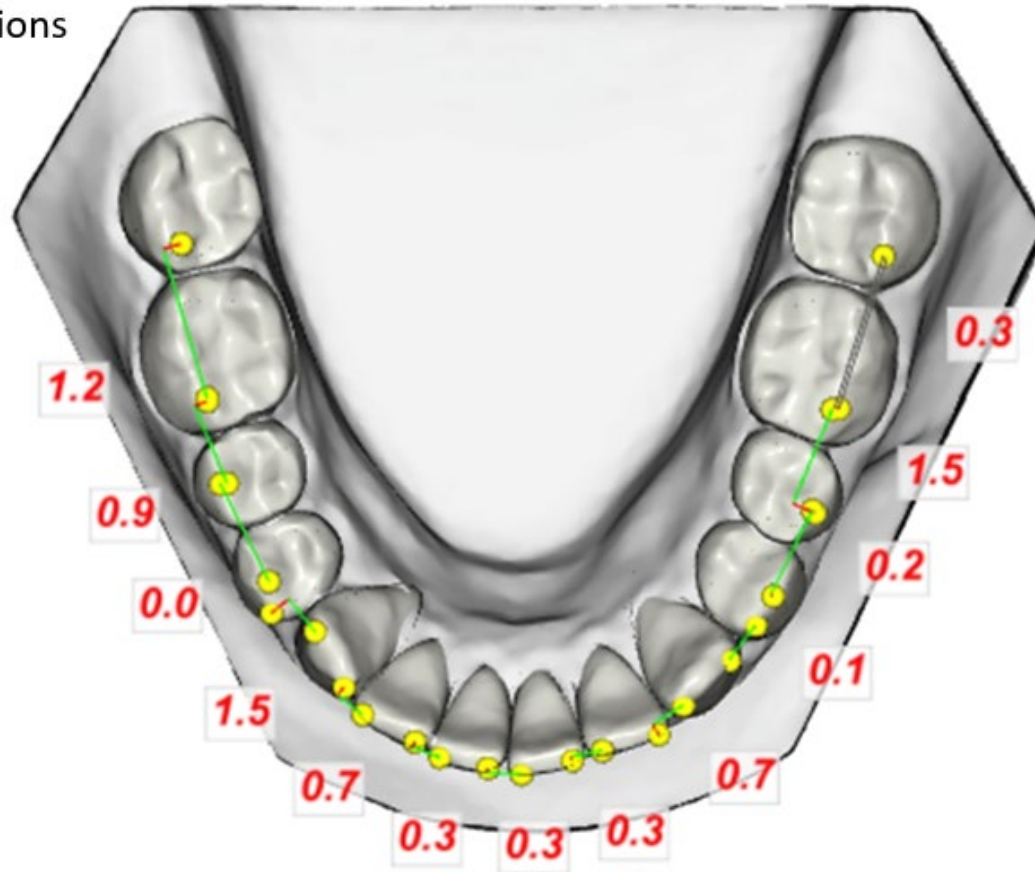
Alignment/Rotations
Measurements



CRE Sample Case

Question 1

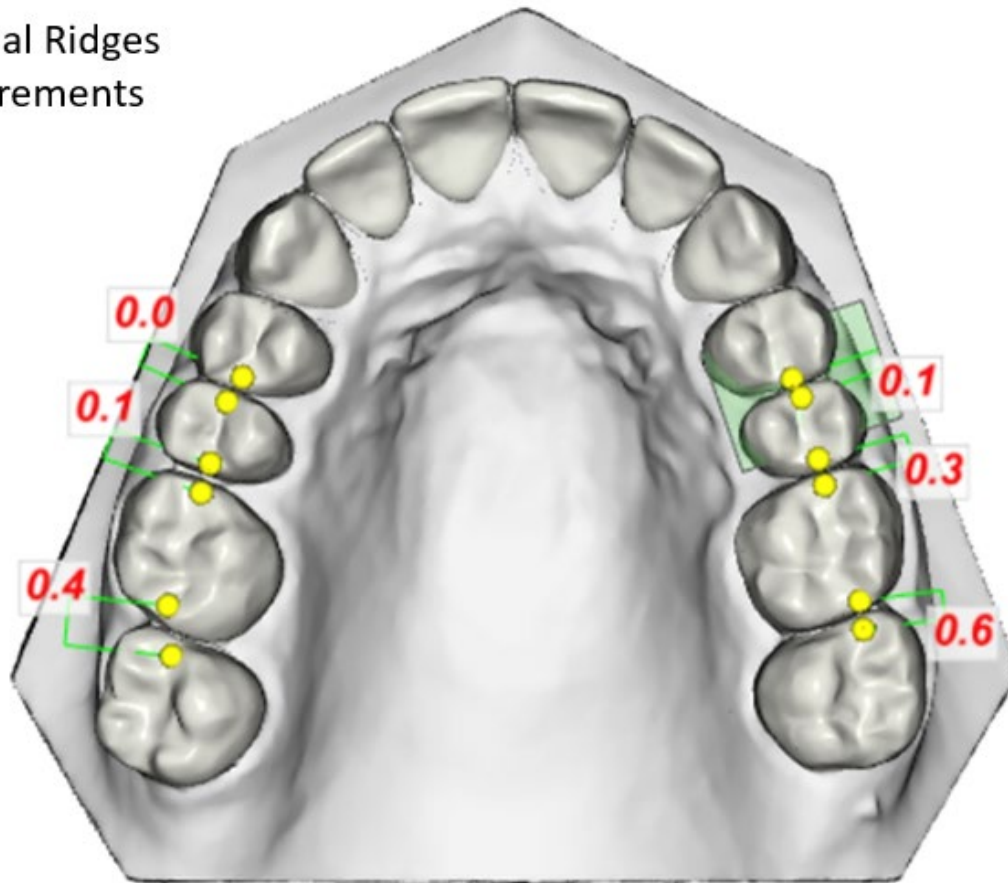
Alignment/Rotations
Measurements



CRE Sample Case

Question 1

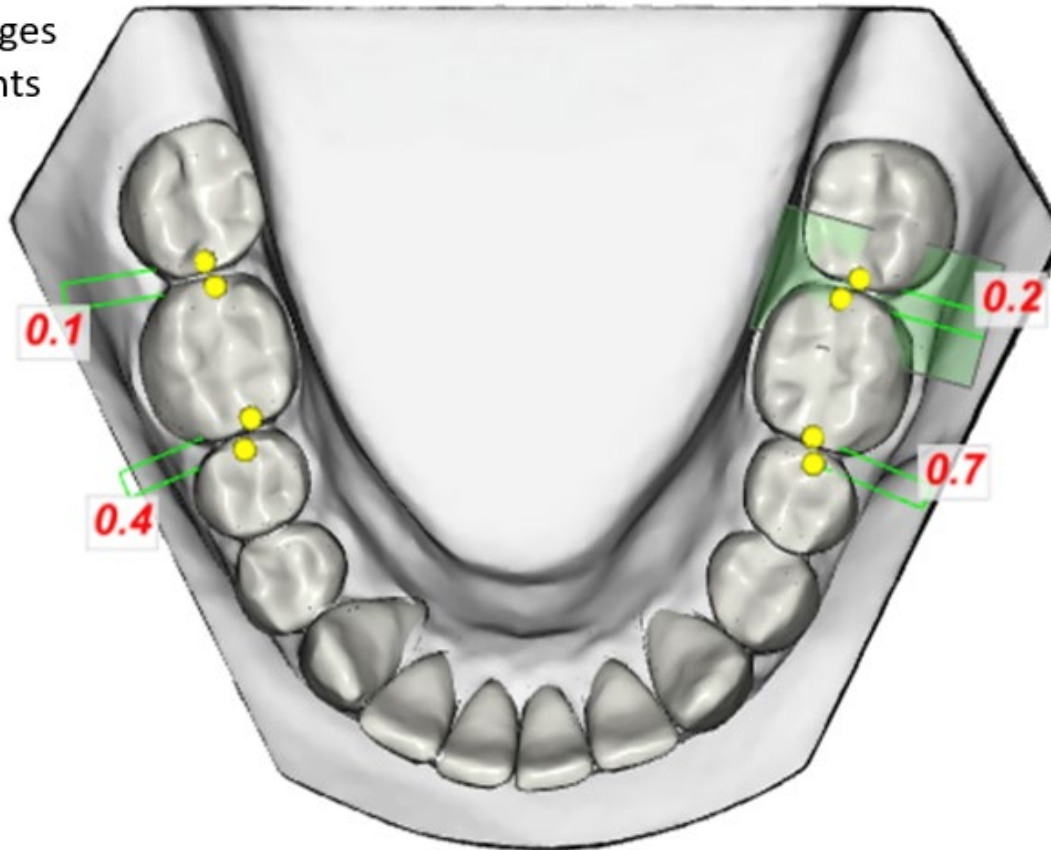
Marginal Ridges
Measurements



CRE Sample Case #1

Question 1

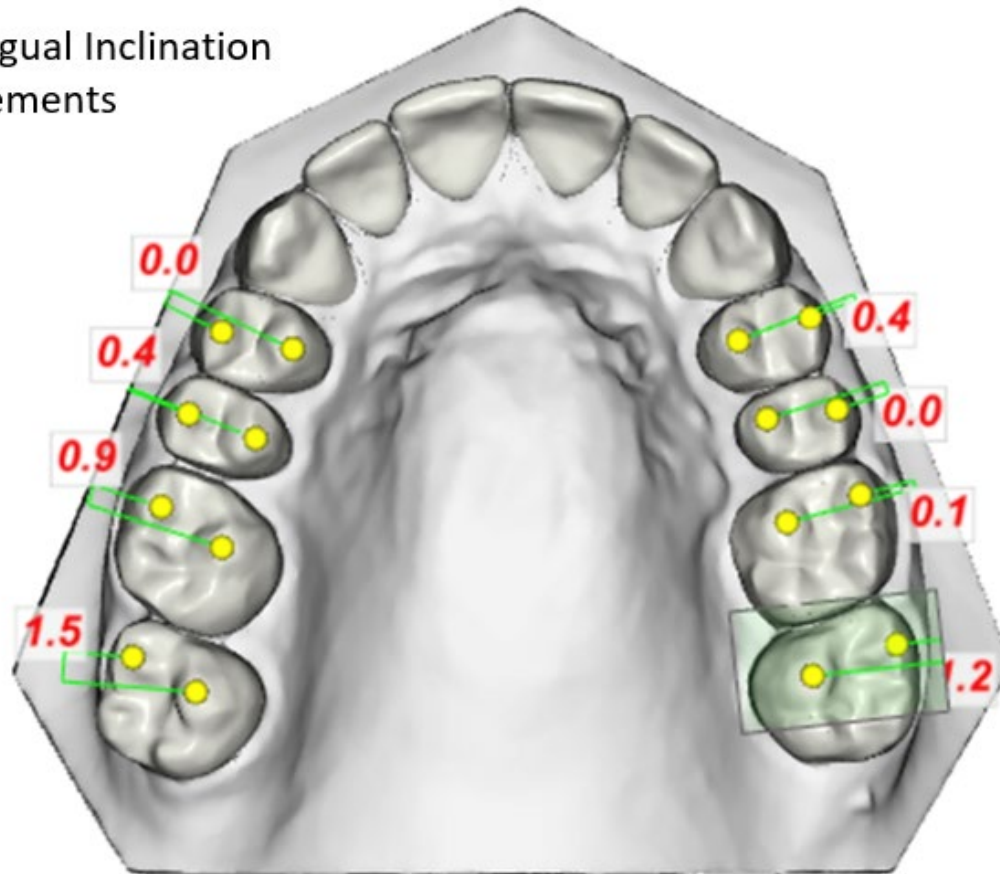
Marginal Ridges
Measurements



CRE Sample Case

Question 1

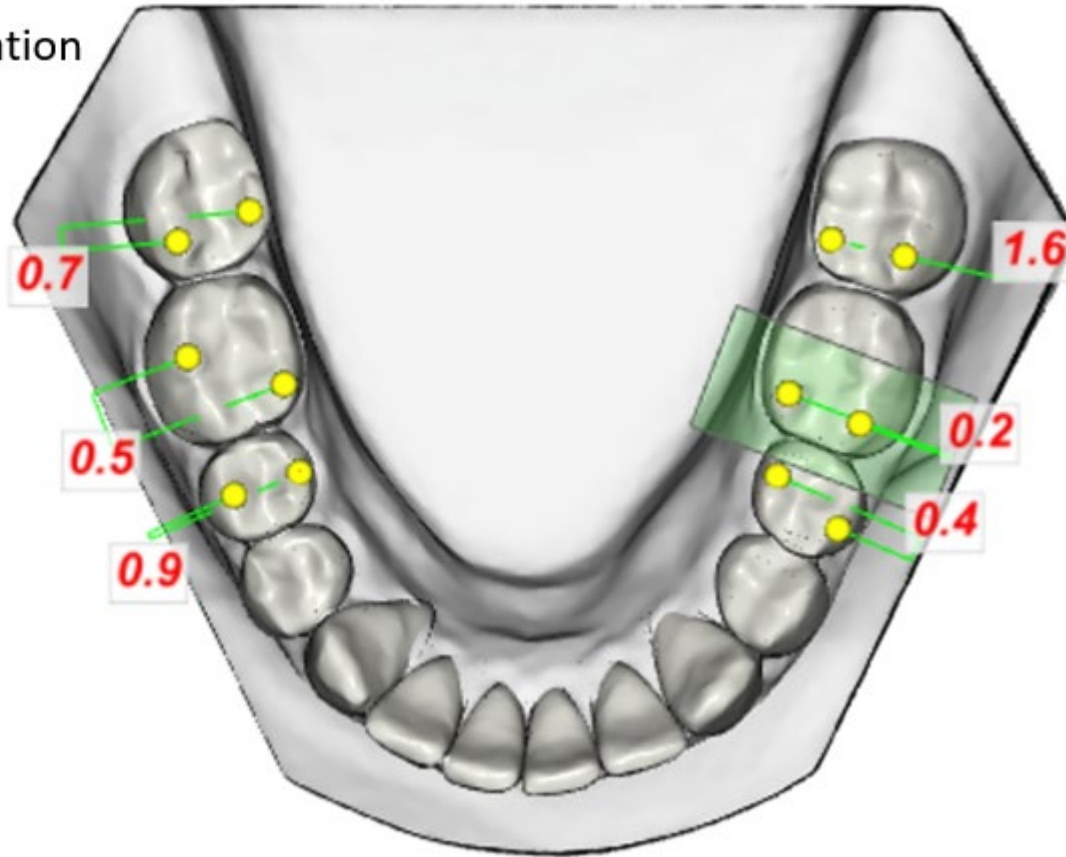
Buccolingual Inclination
Measurements



CRE Sample Case

Question 1

Buccolingual Inclination
Measurements



CRE Sample Case

Question 1

The board expects a fully proficient response for this question to include all of the following:

1. Alignment / Rotations = 11
2. Marginal Ridges = 2
3. Buccolingual Inclination = 3

CRE Sample Case

Question 2

Classification

Domain 4: Critical Analysis and Outcomes Assessment

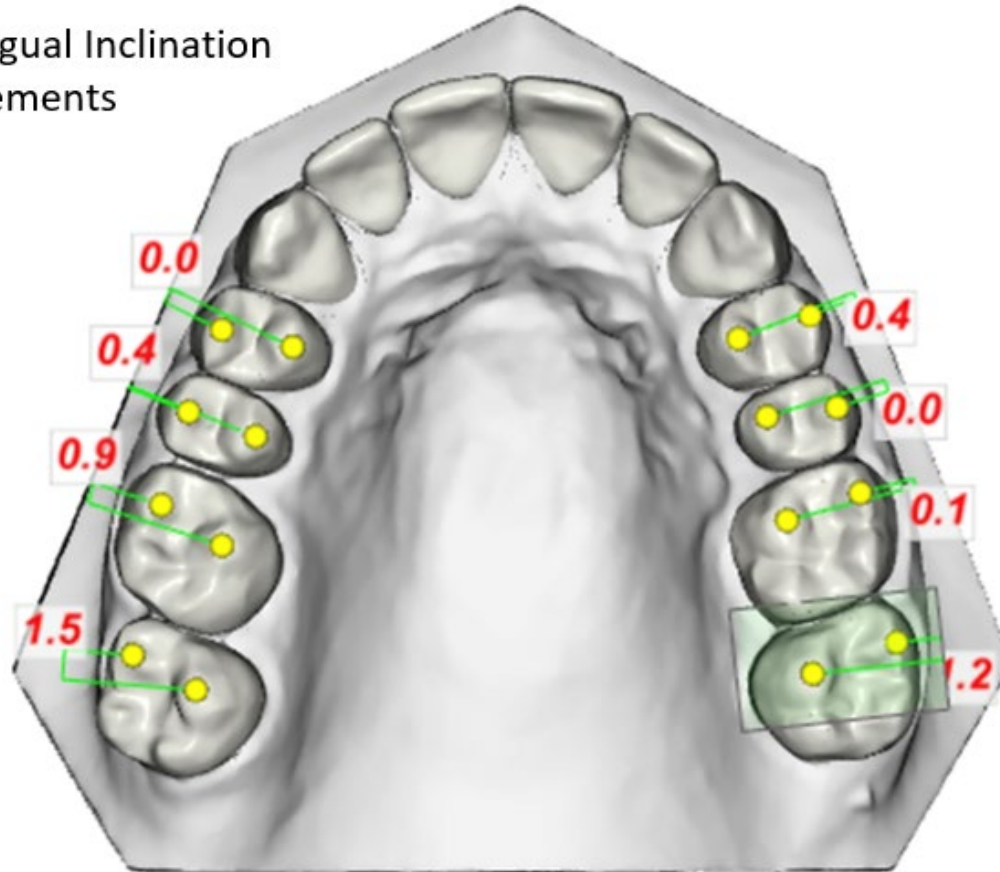
Prompt

Identify actions that could have been taken to improve the CR-Eval score for buccolingual inclination in the maxillary arch. Please respond in numbered list format.

CRE Sample Case

Question 2

Buccolingual Inclination
Measurements



CRE Sample Case

Question 2

The board expects a fully proficient response for this question to include all of the following:

1. Band or bracket maxillary second molars (reposition is acceptable)
2. Completely engage full thickness rectangular archwire into bracket slot
3. Use third order bends to add buccal root torque the second molars
4. Use TPA to add buccal root torque to maxillary second molars (torquing auxiliaries acceptable)

CRE Sample Case

Question 3

Classification

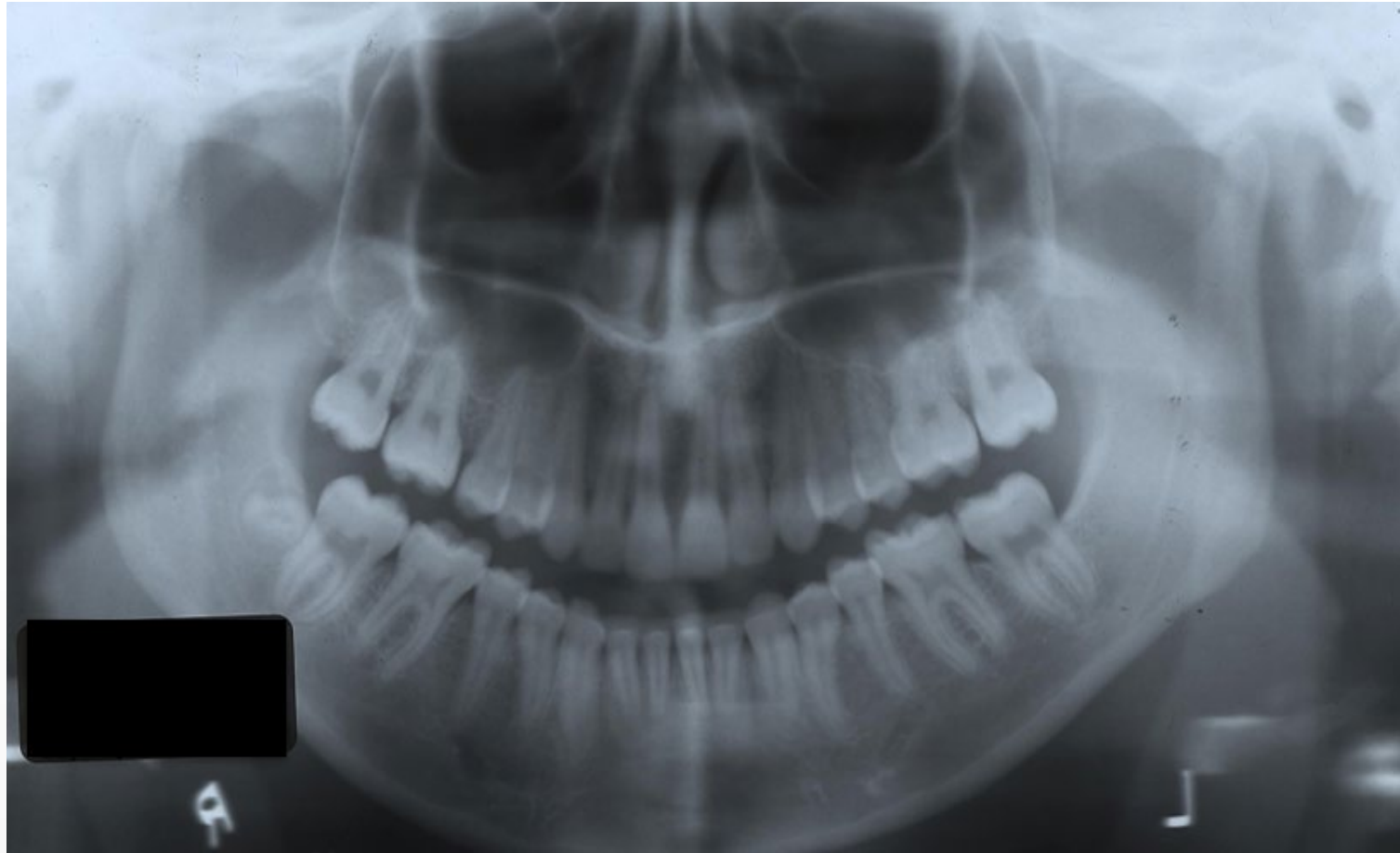Domain 4: Critical Analysis and Outcomes Assessment

Prompt

What is the CR-Eval score for root angulation?

CRE Sample Case

Question 3



CRE Sample Case

Question 3

The CR-Eval score for Root Angulation is 7.

CRE Sample Case E

Sample Case E has been preloaded in the Ortho Share 3D software which may be accessed through the ABO website under **Electronic Cast Radiograph Evaluation (CRE)**. The ABO encourages you to become familiar with this software by practicing with case E and using the videos and instructional materials outlined below:

Instructional Videos (Board Centered Scores for Sample Case E)

Full Continuous Video:

[Ortho Share 3D - Online Tutorial](#)

Individual Video Sections (from video above):

[Introduction / Alignments and Rotations](#)

[Marginal Ridges](#)

[Buccolingual Inclination](#)

[Overjet](#)

[Occlusal Relationship](#)

[Root Angulation](#)

Instructional Materials

[ABO Model Analysis](#)

[ABO CR-Eval PowerPoint Demonstration](#)

[ABO Morphological Points](#)

[ABO CR-Eval Parameters](#)

Case Management Form (CMF)



The highest commitment to excellence.

Case Management Form

Reasons for the ABO Case Management Form

1. Self evaluation (quantified)
2. Evaluation/judgement of each parameter (quantified)
3. Evaluation of records (quantified)
4. Scores can be scored/digitally retrieved (demonstrates trends)
 - A numerical VTO
 - Self evaluation
 - Monitors record quality

Case Management Form (CMF)

MEASUREMENTS				SKELETAL ANALYSIS (S)		SCORING							
				0-Acceptable 1-Unacceptable									
PRE TX	PROG	POST TX	DIFF.	EXAMINEE TX OBJECTIVES		PRE TX OBJ	POST TX RESULT	Score					
				A	A1				B	(A-B)			
CEPHALOMETRIC				SNA°									
				SNB°									
				ANB°									
				SN-MP***									
				FMA°									
				VERT MX									
				VERT MN									
				DENTAL ANALYSIS (D)									
				1 TO NA mm									
				1 TO SN°									
				1 TO NB mm									
				1 TO MP°									
				TRANS MX									
				TRANS MN									
				TRANS ANT									
				CURVE OF SPEE									
				ARCH FORM MN									
				FACIAL ANALYSIS (F)									
				E-LINE Upper									
				E-LINE Lower									
				FACIAL ESTHETICS									
				S-D-F Subtotal				0					
				RECORDS ANALYSIS <i>Shaded areas for examiner only:</i>									
				FACIAL PHOTOS	INTRADRAL PHOTOS	INTRADRAL RADIOGRAPHS	PERIO RECORD	CEPH. & TRACINGS	COUP. TRACINGS	DENTAL CASTS	CASE REPORT	PRESENT. QUALITY	
				PRE TX A FOR PROG A1	0 1	0 1	0 1	0 1	0 1	0 1	0 1	0 1	
				FINAL B	0 1	0 1	0 1	0 1	0 1	0 1	0 1	0 1	SUB-TOTAL RECORDS ANALYSIS
				OVERALL ANALYSIS									
				TREATMENT PLANNING / MECHANOTHERAPY				FINAL TREATMENT RESULTS					
				0	1	2	3	0	1	2	3		
				ACCEPT	DEFICIENCIES			ACCEPT	DEFICIENCIES			SUB-TOTAL OVERALL ANALYSIS	
				TOTAL									

20121006

TOTAL

CMF Sample Case

Question 1

- The examinee will have access to the following records: Initial photo montage, initial intraoral photographs, initial lateral cephalogram, initial cephalometric tracing, and the pre-treatment skeletal analysis (see example below).

	PRE TX A
SNA°	81.0
SNB°	72.0
ANB°	9.0
SN-MP°**	48.0
FMA°	39.0

CMF Sample Case

Question 1

Classification

Domain 2: Treatment Objectives and Planning

Opening Scenario

A 16-year, 2-month-old female presents with the chief complaint that “My teeth stick out.”

Prompt

Using the lateral cephalometric analysis and the CMF chart, identify appropriate skeletal treatment objectives. Please respond in numbered list format below.

Model Responses

The board expects a fully proficient response for this question to include:

- Increase SNB
- Decrease ANB
- Decrease SN-MP
- Decrease FMA

CMF Sample Case

Question 2

- The examinee will have access to the following records: Initial photo montage, initial intraoral photographs, initial lateral cephalogram, initial cephalometric tracing, final photo montage, final intraoral photographs, final lateral cephalogram, final cephalometric tracing, and the pre- /post-treatment skeletal analysis (see example below).

	PRE TX A	PROG A1	POST TX B	DIFF. A-B
SNA°	81.0		81.0	0.0
SNB°	72.0		70.0	-2.0
ANB°	9.0		11.0	2.0
SN-MP°**	48.0		50.0	2.0
FMA°	39.0		41.0	2.0

CMF Sample Case

Question 2

Classification

Domain 4: Critical Analysis and Outcomes Assessment

Opening Scenario

A 16-year, 2-month-old female presents with the chief complaint that “My teeth stick out.”

Prompt

Describe the skeletal changes and your rationale for what occurred. Please respond in numbered list format below.

Model Responses

The board expects a fully proficient response for this question to include:

- Decrease in SNB due to inadequate vertical control
- Increase in ANB due to decrease in SNB (due to/as a result of inadequate vertical control)
- Increase SN-MP due to inadequate vertical control
- Increase in FMA due to inadequate vertical control

CMF Sample Case

Question 3

- The examinee will have access to the following records: Initial photo montage, initial intraoral photographs, initial lateral cephalogram, initial cephalometric tracing, and the pre-treatment dental analysis (see example below).

	PRE TX A
<u>1</u> TO NA mm	9.0
<u>1</u> TO SN°	111.0
- <u>1</u> TO NB mm	16.0
- <u>1</u> TO MP°	107.0

CMF Sample Case

Question 3

Classification

Domain 2: Treatment Objectives and Planning

Opening Scenario

A 16-year, 2-month-old female presents with the chief complaint that “My teeth stick out.”

Prompt

Identify appropriate dental treatment objectives for the variables in the case management table. Please respond in numbered list format below.

Model Responses

The board expects a fully proficient response for this question to include:

- Retract maxillary incisors to NA
- Retract mandibular incisors to NB
- Decrease mandibular incisor proclination to MP
- Decrease maxillary incisor proclination to SN

CMF Sample Case

Question 4

- The examinee will have access to the following records: Initial photo montage, initial intraoral photographs, initial lateral cephalogram, initial cephalometric tracing, final photo montage, final intraoral photographs, final lateral cephalogram, final cephalometric tracing, and the pre- /post-treatment dental analysis (see example below).

	PRE TX A	PROG A1	POST TX B	DIFF. A-B
<u>1</u> TO NA mm	9.0		-2.0	11.0
<u>1</u> TO SN°	111.0		77.0	34.0
- <u>1</u> TO NB mm	16.0		9.0	7.0
- <u>1</u> TO MP°	107.0		97.0	10.0

CMF Sample Case

Question 4

Classification

Domain 4: Critical Analysis and Outcomes Assessment

Opening Scenario

A 16-year, 2-month-old female presents with the chief complaint that “My teeth stick out.”

Prompt

Describe the changes in the maxillary and mandibular incisor position observed in this case. Please respond in numbered list format below.

Model Responses

The board expects a fully proficient response for this question to include:

- Excessive retraction of maxillary incisors
- Lack of torque control in maxillary incisors (resulting in retroclination of the maxillary incisors)
- Retraction of mandibular incisors
- Adequate torque control of mandibular incisors

Case Management Form

- Remember 3 planes of space
- Use precise and concise description
- Use appropriate terminology
- Treatment objectives and treatment plan should be in line with patient's needs not wants
- Actively participate in academic or study club case reviews

Superimpositions



The highest commitment to excellence.

Superimposition Sample Case

Examinees will be presented with a combination of the following case records, as needed:

- Initial photo montage
- Initial intraoral photographs
- Initial panoramic radiograph
- Initial lateral cephalogram
- Initial hand-wrist radiograph
- Final photo montage
- Final intraoral photographs
- Final panoramic radiograph
- Final lateral cephalogram
- Final superimpositions

Superimposition Sample Case

Question 1

Classification

Domain 4: Critical Analysis and Outcomes Assessment

Prompt

Assuming the time between pre- and post-treatment records was 34 months, what dental changes occurred as a direct result of treatment? Please respond in numbered list format below.

Model Responses

The number of responses required to attain a fully proficient or borderline proficient score will depend on the changes that are observed in the superimposition relative to normal growth during the treatment interval.

Superimpositions

- Know radiographic analysis
- Review all 3 ABO superimposition videos (ABO website)
- Master superimposition interpretation skills
- Be able to differentiate changes from growth and treatment mechanics
- Read Buschang/Tadlock Guidelines for Assessing Growth and Development of the Orthodontic Patient. Seminars in Orthodontics, 2017